

## Arabian Medicinal Plants Affected Male Fertility- Plant Based Review (Part 1)

Prof Dr Ali Esmail Al-Snafi

Department of Pharmacology, College of Medicine, University of Thi qar, Iraq.

Corresponding Author: Prof Dr Ali Esmail Al-Snafi

**Abstract:** Medicinal plants have been widely used to enhance or regulate fertility in males. They increased sexual desire (libido), enhanced hormone stimulatory activity (GnRH LH, FSH and testosterone), increased semen volume and increases sperm count, and increased the viability and motility of spermatozoa. On the other hand, large numbers of plants were used as male contraceptive because of their antifertility effects. The current review will highlight the medicinal plants used to enhance fertility in male and that showed male contraceptive effect, which confirmed experimentally and clinically.

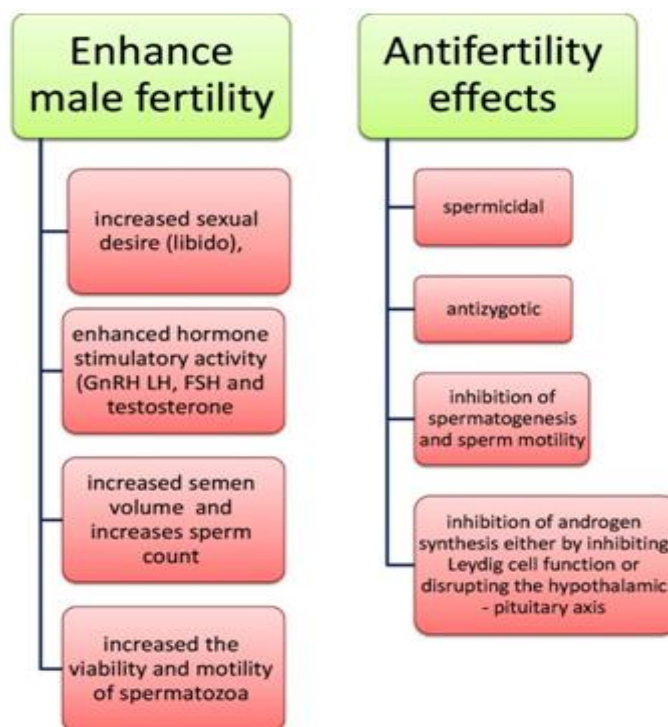
**Keywords** Medicinal plants, male, Fertility, Contraceptive, hormone

Date of Submission: 22-06-2017

Date of acceptance: 05-07-2018

### I. Introduction

Medicinal plants have been widely used to enhance or regulate fertility in males. The beneficial effects of medicinal plants on male fertility were included: increased sexual desire (libido) [1-4], hormone stimulatory activity (GnRH LH, FSH and testosterone)[5-6], increased semen volume and increases sperm count [7-8], and increased the viability and motility of spermatozoa[9]. On the other hand, large numbers of plants were used as male contraceptive because of their antifertility effects. The antifertility effects of medicinal plants included: spermicidal, antizygotic, inhibition of spermatogenesis and sperm motility, inhibition of androgen synthesis either by inhibiting Leydig cell function or disrupting the hypothalamic - pituitary axis, and disruption of seminiferous tubules, erosion of germinal epithelium and disorganized histoarchitecture of the testes [10-13].



**Fig 1: the mechanisms of enhancing fertility and antifertility effects of medicinal plants in males Plants affected male reproductive system:**

### ***Achillea santolina***

The hydroalcoholic extract (300 mg/kg/day intraperitoneally, for 20 days) of *Achillea santolina* caused histological alterations in the seminiferous tubules included disorganized germ epithelium, exfoliation of immature germ cells, germ cell necrosis and increased number of metaphases in germinal epithelium of seminiferous tubules in mice. The authors concluded that *Achilleasantolina* exerted antispermatogenic effect [14-15].

### ***Arctium lappa***

The aqueous extract of *Arctium lappa* L. roots enhanced sexual behavior in male rats. Oral administration of *Arctium lappa* L. roots extract at 600 and 1,200 mg/kg body weight significantly increased the frequencies of mount, intromission, and ejaculation frequency ( $p < 0.05$ ). Administration of the extract also reduced the post-ejaculatory interval [16-19].

### ***Bacopa monniera***

*Bacopa monniera* extracts caused reversible suppression of spermatogenesis and fertility. The treatment caused reduction in motility and viability of the sperms and reduced the number of spermatozoa in caudaepididymidis and testis, and caused alterations in the somniferous tubules in mice [20-21].

### ***Caesalpinia crista***

When *Caesalpinia crista* meal fed to mice and rats, it caused antifertility effect. This effect could be attributed to its contents of gossypol and cyclopropane fatty acids, which has been implicated as an antifertility compounds[22-23]. Electron microscopic examination showed that the graded doses of an alcoholic extract of *Caesalpinia crista* caused morphological changes in the sperm of albino rats including disturbance in the plasma membrane and acrosomal membrane. Considerable changes in the shape and size of the sperm head were observed, with the middle region of the sperm head being slightly constricted dorso-ventrally. Most sperm appeared morphologically abnormal in the head region showing the distortion at the anterior region and bulging of the acrosomal membrane when compared with the control. The authors suggest that such effects might have resulted from general disturbance in proteins and alteration in the caudaepidymal milieu, probably due to an androgen deficiency consequent to the treatment with *Caesalpinia crista* [24].

### ***Capsella bursa-pastoris***

*Capsella bursa-pastoris*, dried and ground, was added at rates of 20 and 40% to the stock diet of male and female mice, found that at the 40% level, both materials impeded ovulation and produced temporary infertility in males and females [25-26].

### ***Carthamus tinctorius***

The effects of aqueous extract of *Carthamus tinctorius* was tested on mouse spermatogenesis. Histopathological criteria such as epithelial vacuolization, sloughing of germ and detachment were significantly decreased in *Carthamus tinctorius* L. treated mice ( $p < 0.001$ ). *Carthamus tinctorius* extract induced formation of multinucleated giant cells in the germinal epithelium. It also caused a significant decrease in seminiferous tubule diameter, seminiferous epithelium height and maturation arrest ( $p < 0.001$ ). Accordingly, *Carthamus tinctorius* extract has toxic effects on mouse testicular tissue, and it was recommended to be use with caution with reproductive problem[27-28].

### ***Chenopodium album***

Ethanollic extract of *Chenopodium album* at doses of 100, 250 and 500mg/kg bw orally, in male albino mice showed significant increase in the mount frequency, intromission frequency, intromission latency as well as aggregate of penile reflexes and significant reduction in the post ejaculatory interval. Moreover 500 mg/kg, orally, was found to be the most effective dose[29]. The ethanolic extract of seeds of *Chenopodium album* was evaluated for its effect on anabolic activity, sexual behavior and sperm count in male rats. Administration of ethanolic extract at a concentration of 200 mg/kg bw resulted in pronounced anabolic effect in treated animals as evidenced by an increased body weight as well as the weight of reproductive organs. Sexual behavior and performance were also markedly improved as reflected in reduction of mount, intromission and post ejaculatory latency. Furthermore, the extract also enhance sperm count [30]. However, on the other hand, the effect of *Chenopodium album* seed extract (CAE) induced sperm death, the effect which is due to (a) lipid peroxidation of the sperm cell membrane, oxidation of some critical cellular proteins and depletion of intracellular reduced glutathione, indicating production of ROS; (b) activation of Mn-SOD and inactivation of catalase favoring endogenous accumulation of H<sub>2</sub>O<sub>2</sub>; (c) generation of O<sup>2-</sup> at an enhanced rate during oxidative stress as evidenced by increased Mn-SOD activity and protein expression; (d) accumulation of ROS in spermatozoa and

(e) increased production of  $O^{2-}$  and  $H_2O_2$  induced apoptosis-like death in sperm cells as observed by DNA ladder formation. Therefore, the sperm death caused by CAE is due to oxidative damage of cellular macromolecules by in situ generation of ROS [31]. Aqueous decoction of *Chenopodium album* seeds (CAD) was assessed for its sperm-immobilizing and contraceptive efficacy in laboratory mammals. The minimum effective concentration of CAD that induced instantaneous immobilization of rat spermatozoa *in vitro* was 2 mg/ml. The mechanism of CAD action involved disintegration of sperm plasma membrane and dissolution of acrosomal cap causing sperm death. Fertilization of oocytes and establishment of implantation were prevented in the uterine horn that was administered with CAD. In rabbit, intravaginal application of CAD significantly blocked the establishment of pregnancy. Accordingly, CAD possesses appreciable spermicidal potential, which may be explored as an effector constituent of vaginal contraceptive [32].

#### ***Cicer arietinum***

The potential aphrodisiac effect of seeds of methanolic extract of *Cicer arietinum* (MECA) was studied in sexually sluggish male albino rats. Sexual behavioral parameters like mount frequency (MF), intromission frequency (IF), ejaculation frequency (EF), ejaculation latency (EL), mount latency (ML) and intromission latencies (IL) were observed in male rats. The male serum cholesterol and testosterone concentrations were also estimated. Oral administration of MECA at 200 and 400 mg/kg body weight was significantly increased the MF, IF, EF and EL ( $P < 0.05$ ) in comparison to control groups, while, ML and IL were significantly decreased ( $p < 0.05$ ). The extract also significantly ( $p < 0.05$ ) increased the serum cholesterol and testosterone levels. From these effects, MECA possessed significant increase in the sexual activity in male rats. The authors postulated that the augmented sexual behavior in male rats might be due to the presence of alkaloids, saponins and flavonoids in MECA [33-34].

#### ***Cistanche tubulosa***

The effect of ethanol extract of *Cistanche tubulosa* (Schenk) R. Wight stem (CTE) was studied on hormone levels and testicular steroidogenic enzymes in rats. It appeared that the administration of CTE (0.4 and 0.8 g/kg) increased sperm count (2.3 and 2.7 folds) and sperm motility (1.3 and 1.4 folds) and decreased the abnormal sperm (0.76 and 0.6 folds) respectively. The serum level of progesterone and testosterone in rats was also increased by CTE administration ( $p < 0.05$ ). Results of immunohistochemistry and western blot analysis confirmed that the expression of CYP11A1, CYP17A1, and CYP3A4 was enhanced by CTE ( $p < 0.05$ ) [35]. The weights of seminal vesicle and prostate gland of castrated young rats were significantly increased by administration of alcohol soluble extract from the decoction of *Cistanche tubulosa*. The phagocytic function of intra-abdominal macrophage in mice was activated by the decoction of *Cistanche tubulosa* [36].

#### ***Citrullus colocynthis***

A crude 50% ethanol extract of *Citrullus colocynthis* Schrad was administered orally to male albino rats for evaluation of antifertility effects. The animals were divided into five groups: group A was a vehicle-treated control group; treatment groups B, C, and D received 100 mg/kg/day *Citrullus colocynthis* extract for periods of 20, 40, and 60 days, respectively, and group E animals received the extract at dose of 100 mg/kg/day for 60 days followed by 60 days of recovery. For androgenicity evaluation of the extract, the animals were divided into four groups: group F animals were castrated 30 days before the experiment to serve as controls, and group G, H, and I were subjected to castration 30 days before the experiments, followed by administration of fruit extract (100 mg/kg/day po), testosterone propionate (0.01 mg/rat/alternate day sc), and fruit extract along with testosterone propionate, respectively, for 30 days. Significant reduction of cauda epididymis sperm motility and density, number of pups, fertility, and circulatory levels of testosterone were observed in all treatment groups. The weights of testes, epididymis, seminal vesicle, and prostate were significantly decreased in groups B, C, and D. The weights of all organs in the different groups of the androgenicity study were markedly decreased in group F when compared with group A, in group G when compared with group F, and in group I when compared with group H, and increased in group H when compared with group F. The serum testosterone levels also showed a similar pattern. The concentration of testicular cholesterol was significantly elevated, while protein, sialic acid, acid and alkaline phosphatase concentrations were decreased. The histoarchitecture of the testes showed degenerative changes in the seminiferous epithelium, arrest of spermatogenesis at the secondary spermatocyte stage, cytolysis, and the lumen filled with eosinophilic material. Histometric parameters (except Sertoli cell) revealed that the nuclear area and the number of round spermatids were markedly altered. All altered parameters restored to normal in group E. No changes were observed in body weight, litter size, hematology, and serum biochemistry. The authors concluded that 50% ethanol extract of *Citrullus colocynthis* showed an antiandrogenic nature, thereby reduced infertility in male albino rats [37-38].

#### **Citrus species**

Studies have shown that lime juice destroys sperm cells, fifty percent of *Citrus aurantifolia* juice wiped out 2000 of sperm cells in 30 seconds. The high acidity of *Citrus aurantifolia* juice may probably responsible for this destruction. The effect of lime juice was studied on the fetal parameters of Sprague-Dawley rats. The estrous cycles of the female rats were studied for the first 16 days to establish cyclicity. The rats were mated with male SD rats of proven fertility on the estrous day (heat period) of estrous cycle. Rats in group I received 1ml of undiluted lime juice while rats in group II received distilled water by gastric gavage. The rats were sacrificed on the 20<sup>th</sup> day of gestation and fetal parameters were evaluated. There was a reduction in the number of fetus of treated pregnant rats when compared to the control. There was a significant reduction in the crown-rump length, weight and umbilical cord length of the fetus when compared with the control. Accordingly, lime juice showed abortifacient effect but no obvious teratogenic effect was observed [39].

The anti fertility effect of *Citrus limonum* seeds was studied on male rats. Male albino rats were orally treated with alcoholic extract and its fractions for 30 and 60 days. Testis and epididymis were removed and tested for sperm count, sperm motility, sperm morphology in addition to histopathological examination. Sperm counts were also studied 90 days after discontinuation of the treatment to see reversibility of effect. 60 days treatment significantly decreased the sperm count. Size and weight of testis and epididymis were reduced indicating atrophic changes in testis and epididymis. It caused drastic effect on sperm motility and morphology which decreased fertility. Sperm counts returned to normal after 90 days [40-41].

### ***Cressa cretica***

Oral administration of a methanolic extract of *Cressa cretica* (whole plant) at a dose level of 100 mg/kg/day for a period of 60 days led to a significant decrease in the weight of testis, epididymis, seminal vesicle, and ventral prostate. *Cressa cretica* reduced the fertility of male rats by 100%. There was a marked reduction in the number of primary spermatocytes, secondary spermatocyte, and spermatids. Sertoli cell counts were significantly decreased. Leydig cell nuclear area and the number of mature Leydig cells were also significantly decreased. The protein, sialic acid, glycogen, and cholesterol content of the testis, the fructose in the seminal vesicle, and protein and sialic acid in the epididymis were significantly decreased. Serum testosterone levels were also reduced after *Cressa cretica* treatment. The RBC and WBC counts, hemoglobin, hematocrit, blood sugar, serum cholesterol, phospholipids, triglyceride, and HDL-cholesterol were within the normal range [42].

The various fractions (FrI 75:25 CHCl<sub>3</sub>:CH<sub>3</sub>OH, FrII 50:50 CHCl<sub>3</sub>:CH<sub>3</sub>OH and FrIII 25:75 CHCl<sub>3</sub>:CH<sub>3</sub>OH) of the *Cressa cretica* whole plant methanol extract were isolated by column chromatography on silica gel. These fractions were used to evaluate their effects on the reproductive functions in male albino rats. Oral administration of fractions I, II and III to male rats (50mg/rat/day) for a period of 60 days did not cause body weight loss, whereas the weight of testes and accessory sex organs were decreased significantly (P≤0.001). Sperm counts of testes and cauda epididymis as well as cauda epididymal sperm motility was also declined significantly (P≤0.001) in comparison to control rats. The serum testosterone production was reduced in treated male rats. The fertility was decreased by 90% in FrI, 100% in FrII and FrIII treated male rats. Total protein, sialic acid, glycogen content of testes and seminal vesicular fructose content were reduced significantly, whereas testicular cholesterol level was increased significantly. The seminiferous tubular diameter and Leydig cell nuclear area were reduced significantly. The population of spermatogenic cells (spermatogonia, preleptotene, pachytene, secondary spermatocytes and round spermatids) were also reduced significantly in comparison to controls [43].

*Cressa cretica* was evaluated for male contraceptive activity due to their rich amount of flavonoids (rutin and scopoletin). After 60 days oral administration of *Cressa* constituents, results showed 100% antifertility activity in male rats with the reduction in testosterone levels and spermatogenic elements [44-45].

### ***Crocus sativus***

The aphrodisiac activities of *Crocus sativus* stigma aqueous extract and its constituents, safranal and crocin, were evaluated in male rats. The aqueous extract (80, 160 and 320 mg/kg bw), crocin (100, 200 and 400 mg/kg bw), safranal (0.1, 0.2 and 0.4 ml/kg), sildenafil (60 mg/kg bw, as a positive control) and saline were administered intraperitoneally to male rats. Mounting frequency (MF), intromission frequency (IF), erection frequency (EF), mount latency (ML), intromission latency (IL) and ejaculation latency (EL) were evaluated. Crocin, at all doses, and the extract, especially at doses 160 and 320mg/kg body wt., increased MF, IF and EF behaviors and reduced EL, IL and ML parameters. Safranal did not show aphrodisiac effects [46].

A randomized, parallel-group, double-blind, placebo-controlled trial was designed to investigate the effects of *Crocus sativus* gel on erectile dysfunction in diabetic men. Patients were randomly allocated to 2 equal groups (with 25 patients each). The intervention group was treated with topical saffron, and the control received a similar treatment with placebo. The 2 groups were assessed using the international index of erectile

function questionnaire before the intervention and 1 month after the intervention. Compared to placebo, the prepared saffron gel significantly improved erectile dysfunction in diabetic patients ( $P < .001$ ) [47-48].

### ***Crotalaria juncea***

The antifertility activity of various extracts of *Crotalaria juncea* seeds was studied in male mice. Adult male mice were gavaged the petroleum ether, benzene and ethanol extracts of *Crotalaria juncea* seeds, 25 mg/100mg/day for 30 days. On day 31 the animals were sacrificed by cervical dislocation and the testes, epididymis, vas deferens, seminal vesicles, prostate gland, bulbourethral gland and levator ani were dissected out and weighed. The organs were processed for biochemical and histological examination. In petroleum ether, benzene and ethanol extracts treated rats, there was a decrease in the weights of testis and accessory reproductive organs. The diameters of the testis and seminiferous tubules were decreased. Spermatogonia, spermatocytes and spermatids in the testis and the sperm count in cauda epididymis were also decreased. There was a significant reduction in the protein and glycogen contents and an increase in the cholesterol content in the testis, epididymis and vas deferens. Of the 3 extracts, the ethanol extract appeared to be the most potent antispermatic extract. When the ethanol extract was tested in immature male mice, it exerted antiandrogenic effect as the weights of accessory organs were reduced [49-50].

Petroleum ether, benzene and ethanolic extracts of *Crotalaria juncea* seeds were administered intraperitoneally at the dose level of 25 mg/100 g body weight to albino male mice for 30 days. The results showed decreased number of spermatogonia, spermatocytes and spermatids in testis along with reduced caudal spermatozoa. Biochemical observations indicated increased level of cholesterol and significant reduction in protein and glycogen content. The increased cholesterol content along with degeneration of Leydig cells indicated inhibition of steroidogenesis. The decrease in the weight of accessory reproductive organs further attributes lowered availability of androgens due likely to inhibition of steroidogenesis. Out of three extracts, ethanolic extract seems to be more potent in antispermatic and antisteroidogenic activities. When ethanolic extract was tested in immature mice for androgenic activity, it showed its antiandrogenic potency as the weight of accessory sex organs were reduced [51].

### ***Cuminum cyminum***

The contraceptive efficacy of *Cuminum cyminum* isolated fractions (CcFr) was investigated in male albino rats. Oral dose of CcFr 50 mg/rat/day for 60 days revealed no significant changes in body weight, while marked abnormalities in spermatogenesis were observed with decreased counts ( $P \leq 0.001$ ) in round spermatids, preleptotene spermatocytes and secondary spermatocytes. Cross sectional surface area of Sertoli cells as well as number of mature Leydig cell were decreased significantly ( $p \leq 0.001$ ). Testicular as well as accessory sex organ biochemical parameters were significantly changed ( $p \leq 0.001$ ). Sperm motility, density and morphology were resulted in 100% negative fertility. Testosterone levels were declined significantly. The authors concluded that *Cuminum cyminum* inhibited spermatogenesis in rats and can be acting as herbal male contraceptive [52-53].

### ***Cydonia oblonga***

The effect of quince (*Cydonia oblonga* Miller) leaf decoction was evaluated in testicular injury and impaired spermatogenesis induced by hypercholesterolemia in rabbits. Mature New Zealand white male rabbits were randomly divided into three groups: group 1 (hypercholesterolemia), group 2 (hypercholesterolemia plus quince treatment), and group 3 (control). Groups 1 and 2 received a cholesterol-enriched diet for six weeks. Group 2 received *Cydonia oblonga* leaf decoction as drinking supplement as well. After six weeks, a normal diet was substituted in groups 1 and 2 for another six weeks. Group 3 (control group) was maintained throughout the study on a regular diet. At the end of the 12<sup>th</sup> week, the left testes of the animals were resected for light microscopic study for evaluation of the maturity of germ cells in seminiferous tubules using Johnsen's score. Increase in intertubular connective tissue and diameter of vessels, abundant spermatogonia and primary spermatocytes along the reduced germinal epithelium were noted in all rabbits of the group 1. The animals in groups 2 and 3 had no significant changes in their testicular sections. The mean Johnsen's score of group 1 ( $4.20 \pm 1.92$ ) was significantly lower than that of group 2 ( $7.33 \pm 0.52$ ) and group 3 ( $7.05 \pm 0.07$ ). ( $p=0.01$ ). According to the results, authors concluded that quince leaf decoction (*Cydonia oblonga*) protected rabbit testes and spermatogenesis from damage induced by hypercholesterolemia [54-55].

The aphrodisiac activity of the hydroalcoholic extract of the fruits of *Cydonia oblonga* was studied in Wistar rats. The extract was administered orally by gavage in the dose of 500 and 800 mg/kg bw per day as a single dose for 28 days. The results showed that after administration of the extract, mounting frequency and the mating performance of the rats increased highly significantly ( $p < 0.01$ ). The extract also influenced the behaviour of treated animals in comparison to non-treated rats in a remarkable manner, making them more attracted to females [56].

### **Phoenix dactylifera (Date palm)**

Pollen of Date palm (500 mg iq) and a combination of zinc sulphate & pollen of Date palm (500 mg iq) in infertile men significantly increased serum LH, FSH, & testosterone levels. It was also, increased significantly sperm count & motility. Sexual desire was also significantly increased. Wives of treated men got pregnancy during the treatment period [57-58].

### **Dactyloctenium aegyptium**

Fertility was estimated in adult male rats treated with whole *Dactyloctenium aegyptium* ethanolic extract 200, 400 and 600 mg/kg body weight. Groups received ethanolic extract of *D. aegyptium* showed significant decrease in serum testosterone levels and increase in serum estrogen levels when compared to control group. The final body weight of all treated groups showed no significant increase in body weight when compared with initial body weights. A significant decrease in weight of testis, epididymis (caput and caudal), vas deferens, seminal vesicle and prostate were noted in all treatment groups when compared with control group. A significant reduction of total sperm count and increase in motility, abnormality of sperm in caput and caudal was observed in all treatment groups compared to control. Histologically, the treated groups showed dose related reduction in the diameter of seminiferous tubules, with reduced layering, less spermatozoa, hypercellularity of Leydig cells with the presence of large multinucleated cells. The administration of ethanolic extract of *D. aegyptium* showed dose dependent decrease in number of pregnant females and number of fetuses. Male rats treated with whole *Dactyloctenium aegyptium* ethanolic extract 200, 400 and 600 mg/kg body weight showed a significant decrease in SOD, catalase, GSH when compared to control group [59-60].

### **Dalbergia sissoo**

The anti-spermatogenic efficacy of ethanol extract of stem bark of *Dalbergia sissoo* Roxb was evaluated. Semen samples were obtained from 15 healthy fertile men aged 25-35 years. Sperm motility was examined by the Sander-Cramer method. A dose-dependent and time-dependent effect of ethanol extract on sperm motility and sperm viability were observed. Various concentrations affected the motility of sperm. Ethanol extract at a concentration of 20 mg/ml caused complete immobilization within 3 minutes. Sperm viability and hypo-osmotic swelling was significantly reduced at this concentration. *In vivo* studies were carried out on Swiss male albino mice. Ethanol extract at a dose of 200 mg/kg body weight resulted in a significant decrease ( $p < 0.001$ ) in weight of the testis and epididymis. A significant decrease ( $p < 0.01$ ) in sperm motility and sperm count in the epididymis were observed. Histological changes in the epididymis and testis were also recorded [61].

Antifertility effects of *Dalbergia sissoo* was investigated in male mice. Adult Parkes strain male mice were orally administered aqueous leaf extract of *Dalbergia sissoo* (50 and 100 mg/kg body weight/day) for 35 days. Motility, viability and number of spermatozoa in the cauda epididymidis; testis histology; serum level of testosterone; and toxicological parameters were evaluated. To assess reversibility, more mice were treated with 100 mg/kg body weight of *Dalbergia sissoo* or distilled water for 35 days and sacrificed 56 days later. The fertility parameters were also assessed separately. Histologically, testes of *Dalbergia*-treated mice showed dissimilar degenerative changes in the seminiferous tubules. Significant reductions were noted (i) in epididymal sperm motility, viability and number, and (ii) in serum level of testosterone in *Dalbergia*-treated mice compared to controls. However, serum levels of alanine aminotransferase, aspartate aminotransferase and creatinine, and haematological parameters were not affected. Also libido of *Dalbergia*-treated males showed no change, but their fertility was markedly suppressed. By 56 days of treatment withdrawal, the alterations induced in fertility parameters were returned to control levels [62-63].

### **Datura species**

The effect alcoholic extract of *Datura fastuosa* (2,4 and 6mg/kg, for 7 weeks) on the fertility was studied in rat males. The results showed that the extract induced significant decrease in concentrations of sperm and normal sperm in all the concentrations in comparing with control group. They also significantly decreased serum levels of testosterone, LH and FSH and weights of the tests and epididymis in the groups treated. The percentage of occurrence of pregnancy was also significantly decreased [64-65].

### **Dodonaea viscosa**

*Dodonaea viscosa* leaf extracts showed antifertility activity in male rats. It decreased sperm count and reproductive organ weights with the appearance of necrotic changes in the seminiferous tubules of testis. Total Protein and glycogen levels were reduced in treated rats compared to the control group. The glycogen depletion in the testis and liver under *Dodonaea viscosa* leaf extracts treatment, was the probable mechanism of the toxic manifestations on male reproductive system [66-67].

### ***Foeniculum vulgare***

The anti-fertility effect of fennel (*Foeniculum vulgare* Mill) seed extract was studied in male rats. Rat groups were orally administered 1 ml of hydro-alcoholic extract of fennel seed in four doses of 35, 70, 140, and 280 mg/kg/bw daily for 60 days. After the last gavage, the rats were anaesthetised and the caudal part of the right epididymis was used for sperm counting. After fixation of the testes, microscopic sections were prepared and histological changes were evaluated. The number of spermatogonia after doses of 140 and 280 mg/kg and Sertoli cells after a dose of 140 mg/kg decreased significantly as compared with the control group ( $P < 0.05$ ). The number of primary spermatocytes and sperm count decreased significantly in the experimental groups (70, 140, and 280 mg/kg) when compared to the control group ( $P < 0.05$ ). Furthermore, thickening of the basement membrane, cell apoptosis, and irregular arrangement of the germinal epithelium were observed in the experimental groups [68-69].

### ***Fumaria officinalis***

The aphrodisiac activities of *Fumaria officinalis* fruit aqueous/ ethanol extract 500mg/kg were studied in rats. *Fumaria officinalis* increase ( $p < 0.05$ ) in mounting behaviour when compared with the control within the first and the third hour respectively. However, it induced no significant difference in mounting behaviour within the first and third hour [70].

### ***Fumaria parviflora***

The effects of *Fumaria parviflora* ethanolic leaves extract on reproductive parameters were studied in adult male rats. Healthy adult male rats were treated with 100, 200 and 400 mg/kg/day of *Fumaria parviflora* leaves extract via gavage for 70 days. The body weight was not affected, while the weights of testis and epididymis were significantly enhanced in rats treated with 200 and 400 mg/kg/day *Fumaria parviflora* extract. No significant changes were observed in seminal vesicle and ventral prostate weight. Significant increase was found in epididymal sperm density and percent of morphologically normal sperm in extract-treated rats. Serum testosterone levels were significantly higher in rats received 200 and 400 mg/kg/day [71].

The effect of *Fumaria parviflora* alcoholic extract on spermatogenesis was studied in rats. *Fumaria parviflora* was administered orally at doses of 750 and 1050 mg/kg bw for 3 days and 250 mg/kg bw for 5 days through oral gavage. Rats were sacrificed on day fifteenth after the first gavage. The weight and volume of the testes was increased in experimental groups but these increases were not significant. Histopathological analysis showed that *Fumaria parviflora* significantly increased the number of spermatogonium, spermatocytes, spermatozooids and Leydig cells [ $P < 0.001$ ] [72].

Co-administration of ethanol *Fumaria parviflora* extract [200 mg kg/ day via gavage for 70 days] with 0.1% lead acetate in drinking water showed a significant increase in testis weight, seminiferous tubules diameter, epididymal sperm count, serum testosterone level, testicular content of superoxide dismutase [SOD] and glutathione peroxidase [GPx], the parameters which decreased in lead-treated rats [73-74].

### ***Glycyrrhiza glabra***

The aphrodisiac activity of aqueous extract of *G. glabra* roots & rhizomes was investigated. 150 mg/kg & 300 mg/kg body wt/day were administered orally by gavage for 28 days. Mount latency, intromission latency, mounting frequency, intromission frequency observed before and during the study at day 0, 7, 10, 14, 21, and 28. The extract reduced significantly mount latency and intromission latency. The extract also increased significantly mounting frequency and intromission frequency [75-76].

### ***Gossypium species***

Gossypol acts as an inhibitor for several dehydrogenase enzymes and has proapoptotic properties, affecting both spermatogenesis and sperm motility [77-78].

Gossypol has been investigated for use as a male contraceptive in a number of experimental studies. Gossypol (10mg/kg bw /day) caused degeneration of spermatocytes in hamsters, (20mg/kg bw /day) caused degeneration of spermatocytes in rats, (25mg/kg bw /day) decreased spermatogenesis, Sertoli cell, and caused seminiferous tubules damage in rats. (10mg/kg bw /day) caused tubular degeneration, reduced testosterone level, and involutions of ventral prostate and seminal vesicles (5, 10 and 20mg/kg bw /day) decreased sperm count and motility, increased abnormal sperm count, and reduced serum levels of testosterone, LH, and FSH in rats, (16.4mg/kg bw/day) reduced sperm production and motility and increased proportion of sperm midpiece abnormalities in bulls, (8mg/kg bw /day) caused primary and secondary sperm abnormalities and increased number of sperm with proximal droplets in bulls [79-84].

Some authors mentioned that the main target organ of gossypol toxicity following repeated exposure to lower doses in rats and humans is the testis with reduced sperm motility, inhibited spermatogenesis and depressed sperm counts [85].

It was used as Male contraceptive method by Chinese , It was noted that men consuming cottonseed oil in their diet showed unusually high infertility rates. Oral administration of gossypol in large scale trials resulted in severe oligozoospermia (< 1 million/ml) at 90% of participants. In 20% of men this effect was irreversible. Because some cases showed severe hypokalemia, WHO recommend the discontinuation of further investigations on gossypol[77-78].

The male contraceptive effects of gossypol were mediated inhibition of release and utilization of ATP by the sperm cells, reduction of cellular and microtubular  $\beta$ -tubular

content in spermatocytes and spermatids, inhibition of calcium influx, and Mg-ATPase and Ca-Mg-ATPase activity in spermatozoid plasmatic membranes. Gossypol produces ultrastructural alterations in the nuclear membrane, endoplasmic reticulum, and mitochondria, decreases cellular oxidase activity and damaged sperms DNA, reduced nuclear expression of androgen receptors in Leydig cells, Sertoli cells, and myoid cells from in rats. It also decreased testosterone, LH and FSH serum levels[82, 85-90].

### ***Helianthus annuus***

In studying the effects of the ethanol extract of the leaves of *Helianthus annuus* on the histology of the testes, blood level of some reproductive hormones and epididymal sperm properties in Wistar rats, It appeared that the extract possessed some anti-fertility effects[91-92].

### ***Hibiscus rosa-sinensis***

The benzene chloroform and alcoholic extracts of the flowers of *Hibiscus rosa sinensis* decreased the spermatogenic elements of testis, and epididymal sperm count, when administered (ip) at two different dose levels of 125 and 250 mg/kg bw to adult male albino mice for 20 days. High content of testicular cholesterol may be due to lowered androgen synthesis[93].

The effect of ethanol, chloroform, ethyl acetate extract of *Hibiscus rosa sinensis* was studied on spermatogenesis and sperm parameters on mice. Administration of 125mg/kg bw of ethanol, chloroform and ethyl acetate extract (Sc) for three consequence days caused marked to significant decrease in testis weight and sperm count and sperm viability[94].

The effects of oral administration of aqueous and alcoholic extracts of flowers of *H. rosa sinensis* (250 mg/kg bw/day, for 30 days) on the reproductive organs of male rats were studied . The results indicated that the weights of the testis, epididymis, ventral prostate, and seminal vesicle of the treated animals were not significantly different from those of the controls. The testis and epididymis of the rats also showed normal histological features, irrespective of treatment. No apparent toxicity of the extracts was discernible[95].

The effect of orally administered aqueous crude extract of *Hibiscus rosa sinensis* (500 mg/kg of bw) on, reproductive organ was studied in mice. The treatment caused reduction in the weight of testis, epididymis and sperm density significantly. Serum testosterone level was declined, the fall in density of sperms and that of testosterone level were correlated to one another Histologically, testis in mice treated with the plant extract showed alteration in the seminiferous tubules included decrease in thickness and density of germinal epithelium and hypertrophy in majority of cells, the lumen showed negligible presence of sperms in the treated animal as compared to control[96].

### ***Hibiscus sabdariffa***

The sub-chronic effect of *Hibiscus sabdariffa* (HS) calyx aqueous extract (1.15, 2.3, and 4.6 g/kg for 12-weeks ) on testes was investigated in rats. Three test groups received different doses of 1.15, 2.30, and 4.60 g/kg based on the LD(50). Results did not show any significant ( $P>0.05$ ) change in the absolute and relative testicular weights, but there was a significant ( $P<0.05$ ) decrease in the epididymal sperm counts in the 4.6 g/kg group, compared to the control. The 1.15 g/kg dose group showed distortion of tubules and a disruption of normal epithelial organization, while the 2.3 g/kg dose showed hyperplasia of testis with thickening of the basement membrane and 4.6 g/kg dose group, showed disintegration of sperm cells[97].

The potential adverse effects of the cold and hot *H. sabdariffa* calyx extracts (200 mg/kg bw, for 4 weeks, orally) on sperm morphology and testicular ultrastructure were studied in albino mice. The results revealed that aqueous extracts of dried calyx of *H. sabdariffa*, either cold or boiled, alter normal sperm morphology and testicular ultrastructure and adversely influence the male reproductive fertility in albino mice[98].

### ***Jussiaea repens***

Oral administration of crude aqueous extract of *Jussiaea repens* to adult male albino rats at the doses of 100 , 200 and 400 mg / kg bw /day for 28 days, caused no significant change in body weight and organ weights like liver, kidney, spleen and heart but the weights of testis and cauda epididymis were significantly reduced, where the weight of adrenal gland showed significant rise in. Epididymal sperm concentration, motility



and viability were significantly reduced but sperm abnormality was markedly increased in and IV. SGOT, SGPT, ALP, ACP, total protein, urea and creatinine level in serum were remained unchanged in treated groups. The fructose content of seminal vesicle and ventral prostate was reduced significantly. Accordingly, the oral administration of aqueous extract of *Jussiaea repens* L may be considered as nontoxic antifertile agent in male rat in a dose dependent manner[99].

The effects of crude aqueous extract of *Jussiaea repens* L (JR) 200 mg/kg bw/day for 28 days in rats) on sperm the DNA integrity of spermatozoa was studied. Toluidine blue (TB), acridine orange (AO) and aniline blue (AB) staining were used to assess sperm chromatin / DNA integrity and comet assay for sperm DNA damage. The results showed that the DNA integrity or denaturation by TB, AO and AB positive staining of spermatozoa of JR treated group were significantly increased when compared with control. But TB positive staining was much higher (34.51%) than AO (27.06 %) and AB (18.91%) positive staining. No denaturation was observed in epididymal spermatozoa of rats after withdrawal of extract treatment. The results of Comet assay also support the reduced change in Head DNA % and increase in Tail DNA %, Tail length (TL), Comet length (CL). All parameters returned almost towards control in withdrawal group, suggested the reversible action of extract[100].

The effects of the crude aqueous extract of *Jussiaea repens* on the normal histoarchitecture of testicular tissue and vis-à-vis functions was investigated. Results showed that when crude aqueous extract of *J. repens* (except root) was fed orally at a dose of 200 mg/kg bw/day for a period of 28 days, caused marked alterations in histology of testis, reduction in seminiferous tubular and Leydig cell nuclear diameter. Spermatogenic stage count showed the arrest of spermatogenesis at stage VII followed by significant reduction in number of sertoli cells and spermatogenic cells. Histological studies of treated testis showed reduction in interstitial tissue with leydig cells, tubular lumen, mature spermatids, thickness of basal lamina with irregular outline and profuse intraepithelial vacuolation. Serum level of testosterone, LH, FSH and testicular testosterone were greatly reduced in treated group. All these effects were restored towards normal after withdrawal of treatment[101].

The effect of crude aqueous extract of *Jussiaea repens* (except root) at the dose of 200mg/kg bw/ day for 28 days in rats was studied on sperm quality and morphological alterations of sperm cells. The results showed that the extract induced alterations of sperm morphology was predominantly of primary abnormalities (40%), which included hook less, banana head, pin head, bent neck, bent tail, head amorphous and presence of cytoplasmic droplets. About 10% secondary abnormalities were found to have coiled tail or head less spermatozoa. The tertiary abnormalities (8%) , tailless or detached head and simple coil tail were also found. The presence of cytoplasmic droplets and disruption of plasma membrane of spermatozoa in treated group also confirmed the potentiality of this plant extract as an anti fertility agent[102].

The probable mode of action of *Jussiaea repens* (except root) as anti fertile agent was studied in rats. The aqueous extract at a dose of 200 mg/kg bw/day orally for 28 days exerted potent anti fertility activity that may be due to decreased testicular ascorbic acid, glycogen,  $\Delta 5\text{-}3\beta$  and  $17\beta$  HSD, G-6PDH, ATPase, LDH activities and increased level of cholesterol, which are directly related to testicular functions. The testicular protein content was unaltered but Zn content was reduced insignificantly than control. Serum triglycerides, VLDL, LDH and G-6PDH were significantly reduced in treated group keeping HDL unaltered, but Zn content was reduced insignificantly. A significant decrease of protein content, Zn, ATPase and LDH activities in epididymis were also observed after treatment, which supported the anti gonadal activity. Altered biochemical parameters may affect the maturation process of spermatogenesis which was reflected through increased percentage of denatured chromatin in spermatozoa. Restoration of all the biochemical parameters in the recovery group supported the reversal effect of the extract after withdrawal of treatment[103].

The effect of crude aqueous extract of *Jussiaea repens* (200mg/kg bw /day for 28 days consecutively) was studied on the histoarchitecture of epididymis and its biochemical alterations in rats. As, histoarchitecture of epididymis and biochemical activities were correlated with sperm maturation, as the relationship between spermatozoa and microenvironment of epididymis during the sperms remain in it, is important for male fertility. Extract caused significant reduction in epididymal sialic acid, glycogen, phospholipid, GSH, and testosterone level. But no change in total lipid and MDA level. Histological studies of epididymis showed the epithelial lining and basement membrane was thin and disrupted, the luminal diameter, epithelial height and nuclear diameter significantly reduced in treated group compare to control[104].

The aqueous extract of *J. repens* at oral dose of 200 mg/kg bw/day for 28 days caused no significant change in body weight but weight of testis and cauda epididymis, sperm motility, total sperm count from cauda epididymis, sperm viability and normal sperms were significantly reduced in treated group. The mating studies with treated group showed 25% having '0' implantation site. Withdrawal of drug for successive 28 days caused marked recovery in testicular and epididymal weight, sperm motility, count, viability and morphology possibly due to inhibition of spermatogenesis and steroidogenesis. The reversal studies caused recovery of reproductive parameters towards normal revealing the nontoxicity[105-106].

## II. CONCLUSION

The great proportion of medicinal plants which used traditionally to solve male reproductive disorders and male infertility have not yet been scientifically evaluated. Therefore, the current review summarized the effects of medicinal plants on male reproductive functions, as investigated by experimental and clinical studies.

## REFERENCES

- [1]. Subramoniam A, Madhavachandran V, Rajasekharan S and Pushpangadan A. Aphrodisiac properties of *Trichopus zeylanicus* extract in male mice. *J Ethnopharmacol* 1997;1 57:21–27.
- [2]. Kumar SKP, Subramoniam A and Pushpangadan P. Aphrodisiac activity of *Vanda tessellata* (roxb.) Hook. Ex don extract in male mice. *Indian J Pharmacol* 2000; 32: 300-304
- [3]. Zheng BL, He K, Kim CH, et al. Effect of a lipidic extract from *Lepidium meyenii* on sexual behavior in mice and rats. *Urology* 2000; 55:598–602.
- [4]. Arletti R, Benelli A, Cavazzuti E, et al. Stimulating property of *Turnera diffusa* and *Pfaffia paniculata* extracts on the sexual behaviour of male rats. *Psychopharmacology* 1999;143:15–19.
- [5]. Xu X, Yin H, Tang D, et al. Application of traditional Chinese medicine in the treatment of infertility. *Hum Fertil* 2003;6:161–168.
- [6]. Guay TA. ED2: erectile dysfunction = endothelial dysfunction. *Endocrinol Metab Clin N Am* 2007; 36:453–463.
- [7]. Gonzales GF, Cordova A, Gonzales C, et al. *Lepidium meyenii* (Maca) improved semen parameters in adult men. *Asian J Androl* 2001; 3:301–303
- [8]. Devi RP, Laxmi V, Charulata C and Rajyalakshmi A. (Alternative medicine): a right choice for male infertility management. *Int Congr Ser* 2004; 1271:67–70.
- [9]. Liu J, Liang P, Yin C, et al. Effects of several Chinese herbal aqueous extracts on human sperm motility in vitro. *Andrologia* 2004; 36:78–83.
- [10]. Tanira MOM, Bashir AK, Dib R, Goodwin CS, Wasfi IA, and Banna NR. Antimicrobial and phytochemical screening of medicinal plants of the United Arab Emirates. *Journal of Ethnopharmacology* 1994; 41(3): 201-205.
- [11]. Pokharkar RD, Saraswat RK and Kotkar S. Survey of plants having antifertility activity from Western Ghat area of Maharashtra state. *Journal of Herbal medicine and Toxicology* 2010; 4(2):71-75.
- [12]. Priya G, Sarvanan K and Renuka C. Medicinal plants with potential anti-fertility activity- A review of sixteen years of herbal medicine research (1994-2010). *International Journal of Pharm Tech Research* 2012; 4(1):481-494.
- [13]. Singh A and Teotia UVS. Effect of Medicinal Plant on Male Reproductive System: A Review. *International Journal For Research In Health Sciences And Nursing* 2017; 3(12): 12-28.
- [14]. Golalipour, MJ, Khori V, Azarhoush R, Nayeypour M and Azadbakht M. Effect of *Achillea santolina* on mice spermatogenesis. *DARU* 2004; 12(1), 36- 39.
- [15]. Al-Snafi AE. Chemical constituents and pharmacological activities of Milfoil (*Achillea santolina*) - A Review. *Int J Pharm Tech Res* 2013; 5(3): 1373-1377.
- [16]. Matsumoto T, Hosono-Nishiyama K, and Yamada H. Antiproliferative and apoptotic effects of butyrolactone lignans from *Arctium lappa* on leukemic cells. *Planta Med* 2006; 72: 276-278.
- [17]. Feng CJ, Yin ZP, We XC, Tao HT, Gui BY and Shan CK. Effect of aqueous extract of *Arctium lappa* L. (burdock) roots on the sexual behavior of male rats. *Complementary and Alternative Medicine* 2012; 12: 8.
- [18]. Farnsworth N. Potential value of plants as sources of new antifertility agents. *J Pharm Sci* 1975; 64: 533-598.
- [19]. Al-Snafi AE. The Pharmacological importance and chemical constituents of *Arctium Lappa*. A review. *International Journal for Pharmaceutical Research Scholars* 2014; 3(1-1): 663-670.
- [20]. Akanksha S and Singh SK. Evaluation of anti-fertility potential of Brahmi in male mouse. *Contraception* 2009; 79: 71-79.
- [21]. Al-Snafi AE. The pharmacology of *Bacopa monniera*. A review. *International Journal of Pharma Sciences and Research* 2013; 4(12): 154-159.
- [22]. Awais M. Medicinal plants of Pakistan. The faculty of mathematics and natural sciences, Oslo University, 2008: 137-163.
- [23]. Al-Snafi AE. Pharmacology and medicinal properties of *Caesalpinia crista* - An overview. *International Journal of Pharmacy* 2015; 5(2): 71-83.
- [24]. Peerzade N, Ahmed RN and Marigoudar SR. Morphological changes induced by *Caesalpinia bonducella* seed extract on rat sperm: scanning electron microscope study. *J Basic Clin Physiol Pharmacol* 2009; 20(4): 309-317.

- [25]. East J. The Effect of certain plant preparations on the fertility of laboratory mammals. *J Endocrinol* 1955; 12(4): 267-272.
- [26]. Al-Snafi AE. The chemical constituents and pharmacological effects of *Capsella bursa-pastoris* - A review. *International Journal of Pharmacology and toxicology* 2015; 5(2):76-81.
- [27]. Mirhoseini M, Mohamadpour M and Khorsandi L. Toxic effects of *Carthamus tinctorius* L. (Safflower) extract on mouse spermatogenesis. *J Assist Reprod Genet* 2012; 29(5): 457-461.
- [28]. Al-Snafi AE. The chemical constituents and pharmacological importance of *Carthamus tinctorius* - An overview. *Journal of Pharmaceutical Biology* 2015; 5(3): 143-166.
- [29]. Al-Snafi AE. The chemical constituents and pharmacological effects of *Chenopodium album* - An overview. *International J of Pharmacological Screening Methods* 2015; 5(1): 10-17.
- [30]. Baldi A and Gupta R. Effect of *Chenopodium album* on sexual behavior and sperm count in male rats. *ISHS Acta Horticulturae 972: II International Symposium on Medicinal and Nutraceutical Plants* 2013.
- [31]. Kumar S, Chatterjee R, Dolai S, Adak S, Kabir SN, Banerjee S and Mondal NB. *Chenopodium album* seed extract-induced sperm cell death: exploration of a plausible pathway. *Contraception* 2008; 77(6): 456-462.
- [32]. Kumar S, Biswas S, Mandal D, Roy HN, Chakraborty S, Kabir SN, Banerjee S and Mondal NB. *Chenopodium album* seed extract: a potent sperm-immobilizing agent both in vitro and in vivo. *Contraception* 2007; 75(1): 71-78.
- [33]. Sajja RB, Venkatesh V, Suneetha B and Srinivas N. Evaluation of aphrodisiac activity of methanolic extract of *Cicer arietinum* seeds in sexually sluggish male albino rats. *Int J Pharm* 2014; 4(4): 309-313.
- [34]. Al-Snafi AE. The medical Importance of *Cicer arietinum* - A review *IOSR Journal of Pharmacy* 2016; 6(3): 29-40.
- [35]. Wang T, Chen C, Yang M, Deng B, Kirby GM and Zhang X. *Cistanche tubulosa* ethanol extract mediates rat sex hormone levels by induction of testicularsteroidogenic enzymes. *Pharm Biol.* 2015; 25:1-7.
- [36]. Zong G, He W, Wu G, Chen M, Shen X and Shi M. Comparison between *Cistanche deserticola* Y. C. Ma and *Cistanche tubulosa* (Shenk) Wight on some pharmacological actions. *Zhongguo Zhong Yao Za Zhi* 1996; 21(7):436-437.
- [37]. Chaturvedi M, Mali PC and Ansari AS. Induction of reversible antifertility with a crude ethanol extract of *Citrullus colocynthis* Schrad fruit in male rats. *Pharmacology* 2003;68(1):38-48.
- [38]. Al-snafi AE. Chemical constituents and pharmacological effects of *Citrullus colocynthis* - A review. *IOSR Journal of Pharmacy* 2016; 6(3): 57-67.
- [39]. Bakare AA, Basse RB, Onyeka CA and Duru FI. Lime Juice (*Citrus aurantifolia*): Effect on fetal parameters of pregnant Sprague-Dawley rats. *International Journal of Medicine and Medical Sciences* 2012; 2(5): 114-116.
- [40]. Kulkarni TR, Mateenuddin M, Bodhankar SL and Saharabudhe RA. Reversible anti- fertility effect of lemon seeds (*Citrus limonum*) in male albino rats. *International Journal of Research in Pharmaceutical and Biomedical Sciences* 2012; 3(2): 545-550.
- [41]. Al-Snafi AE. Nutritional value and pharmacological importance of citrus species grown in Iraq. *IOSR Journal of Pharmacy* 2016; 6(8): 76-108.
- [42]. Gupta RS and Kachhawa JBS. Effect of *Cressa cretica* Linn. methanolic extract on testicular function of albino rats. *Pharmaceutical Biology* 2006; 44(5): 382-88.
- [43]. Gupta RS and Kachhawa JBS. Contraceptive evaluation of isolated fractions of *Cressa cretica* (L.) whole plant methanol extract in male albino rats. *Planta Med* 2008; 74(9): PA324.
- [44]. Kachhawa JBS and Gupta RS. Male contraceptive activity of phytochemical constituents of *Cressa cretica* (convolvulaceae). *Planta Med* 2010; 76: 79.
- [45]. Al-Snafi AE. The chemical constituents and therapeutic importance of *Cressa cretica*- A review . *IOSR Journal of Pharmacy* 2016; 6(6): 39-46.
- [46]. Hosseinzadeh H, Ziaee T and Sadeghi A. The effect of saffron, *Crocus sativus* stigma, extract and its constituents, safranal and crocin on sexual behaviors in normal male rats. *Phytomedicine* 2008; 15(6-7): 491-495.
- [47]. Mohammadzadeh-Moghadam H, Nazari SM, Shamsa A, Kamalinejad M, Esmaeeli H, Asadpour AA and Khajavi A. Effects of a topical saffron (*Crocus sativus* L) gel on erectile dysfunction in diabetics: A randomized, parallel-group, double-blind, placebo-controlled trial. *J Evid Based Complementary Altern Med* 2015, doi:10.1177/2156587215583756
- [48]. Al-Snafi AE. The pharmacology of *Crocus sativus*- A review. *IOSR Journal of Pharmacy* 2016; 6(6): 8-38.
- [49]. Vijaykumar B, Sangamma I, Sharanabasappa A and Patil SB. Antispermatic and hormonal effects of *Crotalaria juncea* Linn. seed extracts in male mice. *Asian J Androl* 2004; 6(1): 67-70.

- [50]. Al-Snafi AE. The contents and pharmacology of *Crotalaria juncea*- A review. IOSR Journal of Pharmacy 2016; 6(6): 77-86.
- [51]. Vijaykumar B, Sangamma I, Sharanabasappa A and Patil SB. Antifertility activity of various extracts of *Crotalaria juncea* Linn., seeds in male mice. Philippine Journal of Science 2003; 132(1): 39-46.
- [52]. Saxena P, Gupta R and Gupta RS. Contraceptive studies of isolated fractions of *Cuminum cyminum* in male albino rats. Nat Prod Res 2015; 29(24): 2328-2331.
- [53]. Al-Snafi AE. The pharmacological activities of *Cuminum cyminum* - A review. IOSR Journal of Pharmacy 2016; 6(6): 46-65.
- [54]. Ashrafi H, Ghabili K, Hemmati AA, Jouyban A, Shoja MM, Aslanabadi S, Adl FH, Ghavimi H and Hajhosseini L. The effect of quince leaf (*Cydonia oblonga* miller) decoction on testes in hypercholesterolemic rabbits: a pilot study. Afr J Tradit Complement Altern Med 2012; 10(2): 277-282.
- [55]. Al-Snafi AE. The medical importance of *Cydonia oblonga*- A review. IOSR Journal of Pharmacy 2016; 6(6): 87-99.
- [56]. Aslam M and Sial AA. Effect of hydroalcoholic extract of *Cydonia oblonga* Miller (Quince) on sexual behaviour of Wistar rats. Adv Pharmacol Sci 2014; doi: 10.1155/2014/282698.
- [57]. Al-Snafi AE, Bahaadeen EF, Marbeen MI and Marbut MM. The effect of date palm pollens and zinc sulphate in the treatment of human male infertility. Tikrit Journal of Pharmaceutical Sciences 2006; 2(1): 31-34.
- [58]. Marbin M Ideen and Al-Snafi A E. The probable therapeutic effects of Date palm pollens in treatment of male infertility. Tikrit Journal of Pharmaceutical Sciences 2005;1 (1): 1-6.
- [59]. Naik BS, Dangi NB, Sapkota P, Wagle N, Nagarjuna S, Sankaranand R and Kumara BA. Phytochemical screening and evaluation of anti-fertility activity of *Dactyloctenium aegyptium* in male albino rats. Asian Pacific Journal of Reproduction 2016; 5(1): 51-57.
- [60]. Al-Snafi AE. The pharmacological potential of *Dactyloctenium aegyptium*- A review. Indo Am J P Sci 2017; 4(01): 153-159.
- [61]. Vasudeva N and Vats M. Anti-spermatogenic activity of ethanol extract of *Dalbergia sissoo* Roxb. stem bark. Journal of Acupuncture and Meridian Studies 2011; 4: 116-122.
- [62]. Verma HP and Singh SK. Effect of aqueous leaf extract of *Dalbergia sissoo* Roxb. on spermatogenesis and fertility in male mice. Eur J Contracept Reprod Health Care 2014; 19(6):475-486.
- [63]. Al-Snafi AE. Chemical constituents and pharmacological effects of *Dalbergia sissoo* - A review. IOSR Journal of Pharmacy 2017; 7(2): 59-71.
- [64]. Al-Mailay HKA. The effect *Datura Fastuosa* L. alcohol extract on the fertility of white rats males. J al-Qadisiyah for Pure Sciences 2008; 13(3): 1-11.
- [65]. Al-Snafi AE. Medical importance of *Datura fastuosa* (syn: *Datura metel*) and *Datura stramonium* - A review. IOSR Journal of Pharmacy 2017; 7(2):43-58.
- [66]. Kumar RV, Reddy GVR, Sathyanarayana J, Bikshapathi T and Reddy MK. Effect of *Melia azedarach* and *Dodonaea viscosa* aqueous leaf extracts on fertility in male albino rats. Indian J.Pharm.Biol.Res. 2013; 1(4):7-12.
- [67]. Al-Snafi AE. A review on *Dodonaea viscosa*: A potential medicinal plant. IOSR Journal of Pharmacy 2017; 7(2): 10-21.
- [68]. Al-Snafi AE. The chemical constituents and pharmacological effects of *Foeniculum vulgare* - A review. IOSR Journal of Pharmacy 2018; 8(5): 81-96.
- [69]. Mansouri E, Asadi-Samani M, Kooti W, Ghasemiboroon M, Ashtary-Larky D, Alamiri F, Afrisham R, and Noohi ZH. Anti-fertility effect of hydro-alcoholic extract of fennel (*Foeniculum vulgare* Mill) seed in male Wistar rats. Journal of Veterinary Research 2016; 60(3):357-363.
- [70]. Mukhtar GZ, Chrioma BA, Zainab R, Muhmmad AI, Yusuf I and Isa Y. *Cinnamomun cassia*, *Ficus carica* and *Fumaria officinalis* possesses aphrodisiac activity in male Wister rats. Annals of Experimental Biology 2015; 3 (3):14-17.
- [71]. Dorostghoal M, Seyyednejad SM, Khajehpour L and Jabari A. Effects of *Fumaria parviflora* leaves extract on reproductive parameters in adult male rats. Iran J Reprod Med 2013; 11[11]:891-898.
- [72]. Nasrabadi MH, Aboutalebi H and Naseri M. Effect of *Fumaria parviflora* alcoholic extract on male rat's reproductive system. Journal of Medicinal Plants Research 2010; 6[10]: 2004- 2010.
- [73]. Dorostghoal M, Seyyednejad SM and Jabari A. Protective effects of *Fumaria parviflora* L. on lead-induced testicular toxicity in male rats. Andrologia 2014; 46[4]: 437-446.
- [74]. Al-Snafi AE. *Fumaria parviflora*- A review. Indo Am J P Sc 2018; 5(3): 1728-1738.
- [75]. Sharma K, Thakur M, Chauhan NS and Dixit VK. Evaluation of the anabolic, aphrodisiac and reproductive activity of *Anacyclus Pyrethrum* DC in male rats. Sci Pharm 2009; 77: 97-110.

- [76]. Liu GZ, Lyle KC and Cao J. Experiences with gossypol as a male pill. *Am J Obstet Gynecol* 1987; 157: 1079-1081.
- [77]. Al-Snafi AE. *Glycyrrhiza glabra*: A phytochemical and pharmacological review. *IOSR Journal of Pharmacy* 2018;8(6): 1-17.
- [78]. Hahn DW, Rusticus C and Probst A. Antifertility and endocrine activities of gossypol in rodents. *Contraception* 1981; 24(1): 97-105.
- [79]. Heywood R, Lloyd GK, Majeed SK and Gopinath C. The toxicity of gossypol to the male rat. *Toxicology* 1986; 40(3): 279-284.
- [80]. Al-Snafi AE. Chemical constituents and pharmacological activities of *Gossypium herbaceum* and *Gossypium hirsutum* - A review. *IOSR Journal of Pharmacy* 2018; 8(5): 64-80.
- [81]. G'afvels M, Wang J, Bergh A, Damber JE and Selstam G. Toxic effects of the antifertility agent gossypol in male rats. *Toxicology* 1984; 32(4): 325-333.
- [82]. El-Sharaky AS, Newairy AA, Elguindy NM and Elwafa AA. Spermatotoxicity, biochemical changes and histological alteration induced by gossypol in testicular and hepatic tissues of male rats. *Food and Chemical Toxicology* 2010; 48(12): 3354-3361.
- [83]. Chenoweth PJ, Risco CA, Larsen RE, Velez J, Tran T and Chase Jr CC. Effects of dietary gossypol on aspects of semen quality, sperm morphology and sperm production in young Brahman bulls. *Theriogenology* 1994; 42(1): 1-13.
- [84]. Hassan ME, Smith GW, Ott RS, et al. Reversibility of the reproductive toxicity of gossypol in peripubertal bulls. *Theriogenology* 2004; 61(6): 1171-1179.
- [85]. Scientific Opinion of the Panel on Contaminants in the Food Chain on a request from the European Commission on gossypol as undesirable substance in animal feed. *The EFSA Journal* 2008; 908: 1-56.
- [86]. Ueno H, Sahni MK, Segal S and Koide SS. Interaction of gossypol with spermmacromolecules and enzymes. *Contraception* 1988; 37(3): 333-341.
- [87]. Teng CS. "Reversible changes in the content of cellular and microtubular tubulin in spermatogenic cells after gossypol treatment. *Contraception* 1997; 55(1): 41-46.
- [88]. Breitbart H, Rubinstein S and Nass-Arden L. Effect of gossypol-acetic acid on calcium transport and ATPase activity in plasma membranes from ram and bull spermatozoa. *International Journal of Andrology*. 1984; 7(5): 439-447.
- [89]. Breitbart H, Mayevsky A and Nass-Arden L. Molecular mechanisms of gossypol action on sperm motility. *International Journal of Biochemistry*. 1989; 21(10): 1097-1102.
- [90]. Hoffer Ap. Effects of gossypol on the seminiferous epithelium in the rat: a light and electron microscope study. *Biology of Reproduction* 1983; 28(4): 1007-1020.
- [91]. Ejebe DE, Siminialayi IM, Nwadito C, Emudainowho JOT, Akonghrere R, Ovuakporaye SI, et al. Effects of ethanol extract of leaves of *Helianthus annuus* (Common sunflower) on the reproductive system of male Wistar rats: testicular histology, epididymal sperm properties and blood levels of reproductive hormones. *Biomed Pharmacol J* 2008; 1(1): 65-78.
- [92]. Al-Snafi AE. The pharmacological effects of *Helianthus annuus*- A review. *Indo Am J P Sc* 2018; 5(3):1745-1756.
- [93]. Reddy CM, Murthy DR and Patil SB. Antispermatic and androgenic activities of various extracts of *Hibiscus rosa sinensis* in albino mice. *Indian J Exp Biol* 1997; 35(11): 1170-1174.
- [94]. Sharawy S and Ibrahim NA. The Effects of *Hibiscus rosa sinensis* Flower Extracts on Spermatogenesis and Sperm Parameters of Mice. *G J B A H S* 2014; 3(2):32-35.
- [95]. Tan CH. Is *Hibiscus rosa sinensis* Linn. a potential source of antifertility agents for males? *Int J Fertil* 1983;28(4):247-248.
- [96]. Mishra N, Tandon VL and Munjal A. Evaluation of medicinal properties of *Hibiscus rosa sinensis* in male Swiss albino mice. *International Journal of Pharmaceutical and Clinical Research* 2009; 1(3): 106-111.
- [97]. Orisakwe OE, Husaini DC and Afonne OJ. Testicular effects of sub-chronic administration of *Hibiscus sabdariffa* calyx aqueous extract in rats. *Reprod Toxicol* 2004;18(2):295-298.
- [98]. Mahmoud YI. Effect of extract of *Hibiscus* on the ultrastructure of the testis in adult mice. *Acta Histochem* 2012;114(4):342-348.
- [99]. Pradhan N, Ghoshal S and Chakraborty I. *Jussiaea repens* L is a nontoxic anti gonadal fertile herb- a dose dependent study on male rats. *Int J Pharm Bio Sci* 2013; 4(2): 131 - 143.
- [100]. Ghosal S, Chakraborty I and Pradhan NK. Effects of *Jussiaea repens* L on sperm DNA integrity in male albino rats. *IJPSR* 2016; 7(11): 4660-4668.
- [101]. Ghosal S, Chakraborty I and Pradhan N. Reversible action of *Jussiaea repens* (L) induced alteration of histoarchitecture vis-à-vis functions in testicular tissues of rat. *World Journal of Pharmaceutical Research* 2015; 4(5): 1667 -1687.

- [102]. Ghosal S, Chakraborty I and Pradhan NK: *Jussiaea repens* L induced morphological alterations in epididymal spermatozoa of rat. *International Journal of Pharmaceutical Sciences Review and Research* 2013; 22(2): 288-295.
- [103]. Chakraborty I, Ghosal S and Pradhan NK. *Jussiaea repens* (L) acts as an antifertility agent – a search for herbal male contraceptive. *Int J Pharm Sci Rev Res* 2014; 24(2): 288-296.
- [104]. Ghosal S, Chakraborty I and Pradhan N. Histoarchitecture and biochemical studies of epididymis in male rats induced by aqueous extract of *Jussiaea repens* L. *JPSR* 2016; 7(5): 2209-2218.
- [105]. Ghoshal S, Das A, Bhattacharya K, Mondal M, Chakraborty I, Masanta N and Pradhan N. *Jussiaea repens* as a herbal contraceptive- a mating study in male rats. *J Environ & Sociobiol* 2015; 12(1): 123-131.
- [106]. Al-Snafi AE. Constituents and pharmacological importance of *Jussiaea repens* - A review. *Indo Am J P Sc* 2018; 5 (4): 2206-2212.

IOSR Journal of Pharmacy (IOSR-PHR) is UGC approved Journal with SI. No. 5012

Prof Dr Ali Esmail Al-Snafi "Arabian Medicinal Plants Affected Male Fertility- Plant Based Review (Part 1)L." *IOSR Journal of Pharmacy (IOSRPHR)*, vol. 8, no. 07, 2018, pp. 63-76.