

See discussions, stats, and author profiles for this publication at: <https://www.researchgate.net/publication/331384670>

621 EVALUATION OF HISTOPATHOLOGICAL CHANGES OF HYDATID CYST ON KIDNEY OF EXPERIMENTALLY INFECTED MICE

Article in *Basrah Journal of Veterinary Research* · January 2018

CITATIONS

0

READS

10

2 authors, including:



Amal Khudair Khalaf

University of Thi-Qar ,college of medicine, Iraq

42 PUBLICATIONS 16 CITATIONS

SEE PROFILE

Some of the authors of this publication are also working on these related projects:



Hydatid cyst [View project](#)



The future of philosophy (مستقبل الفلسفة) [View project](#)

EVALUATION OF HISTOPATHOLOGICAL CHANGES OF HYDATID CYST ON KIDNEY OF EXPERIMENTALLY INFECTED MICE

* Amal KH. Khalaf and ** Salih K. Majeed

*Department of microbiology , College of Medicine, University of Thi-Qar
Thi-Qar, Iraq.

** college of Veterinary Medicine, University of Basrah, Basrah, Iraq

Keywords: Hydatid cyst, kidney, mice.

Corresponding Author: amalkhudair111@yahoo.com

ABSTRACT

Hydatidosis is an endemic disease in Iraq till now and it causes highly economic losses . the aim of the following study was to investigate the histopathological effect of hydatid cyst on kidney function .

11% total percentage were recorded among kidney of experimentally infected male mice with hydatid cyst in the current study and many pathological changes were also reported.

The present study has explained that the infection with hydatid disease affect on the kidney function after examination of Blood urea nitrogen that related to kidney function and reporting increase of its level .

INTRODUCTION

Hydatid disease, hydatidosis, cystic echinococcosis, unilocular hydatid disease , *E. granulosus* Echinococcosis , and Al - akyas al-mai'yah' and 'al atash' all terms describing infections which are caused by cestodes of the genus *Echinococcus* particularly *E. granulosus* (1). The organ most commonly involved is the liver (50-70%), followed by lungs (20-30%) and other organs (like the spleen, kidney, heart, bones, central nervous system etc.) in less than 10% of the cases (16).

The hydatid cyst remains a significant public health hazard in endemic areas such as Iraq , Turkey, the Middle East, South America, New Zealand , Africa , China, northern Kenya, Australia, and other sheep-raising areas (1) . As an endemic disease, it causes social and economic losses for countries. WHO reports stated that approximately 100,000 people in the world are infected with this disease every year (10) which is common in rural populations of underdeveloped countries because of their close association with domestic and wild animals (11,12).

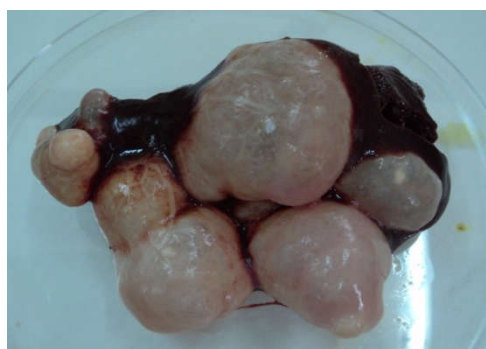MATERIALS AND METHODS

Parasite Materials and Protoscolices Preparation

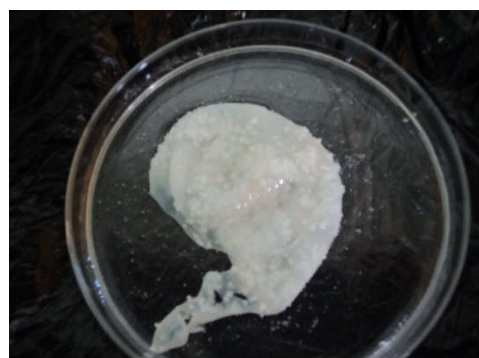Fresh hydatid cysts were obtained from livers and lungs of naturally-infected sheep, which had been slaughtered at local abattoirs in Basrah city, human hydatid cysts were obtained from Al- Sadir teaching hospital in Basrah city. They were wrapped carefully in clean plastic bags, placed in an ice box, and transported to the Department of Biology, College of Education, Basrah University, where protoscolices were isolated according to (14) method . Protoscolices were counted according to method cited by (2). The viable protoscolices were counted in 1ml based on the formula :

Viability in 1 ml = number of protoscolices in (10 µl) × 100

Eight male of *Mus musculus* mice Balb\C strain were injected with 0.2 ml 480/ ml (2400/5ml rate of viability) of protoscolices intraperitoneally and consider as positive group and left for six months. also, negative control group were included in the study and involve eight of uninfected male mice.



Hydatid cysts after removal from liver



Germinal layer containing protoscolices removed from hydatid cyst

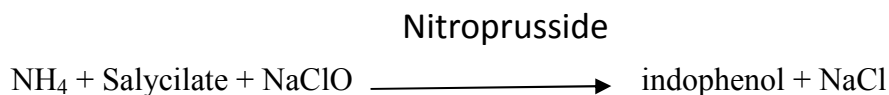
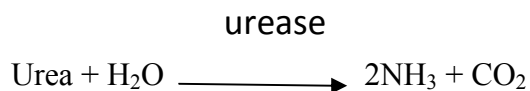
The Study of the effect of infection on blood urea nitrogen (BUN):

Blood samples were obtained from the heart of each animal after anesthesia using 1ml volume syringe. The samples were collected in vials without any anticoagulant for the determination blood urea nitrogen (BUN) . blood urea nitrogen (BUN) was tested by the spectrophotometer using a suitable kit for each of BUN based on (13) methods as follows:

Blood Urea Nitrogen Test (BUN)

BUN was used to determine the functional status of the kidney and it was measured by using a special kit (Biomerieux \ France) as follow :

Test Principle :



Test Procedure

Solution	Blank	Standard	Sample
Working reagent	1000 µl	1000 µl	1000 µl
Sample	-	-	10 µl
Standard	-	10 µl	-
The tubes were mixed and incubated 5 minutes at 37.			
NaoH	1000 µl	1000 µl	1000 µl

The tubes were mixed and incubated for 5 minutes at 37°C. Within 60 minutes the absorbance of sample was read against the reagent blank by the spectrophotometer at a 600 nm wave length.

Calculation

ΔA Sample

$$\frac{\Delta A \text{ Sample}}{\Delta A \text{ Standard}} \times \text{Standard concentration} = \text{urea concentration}$$

ΔA Standard

Standard concentration: 50 mg/dl.

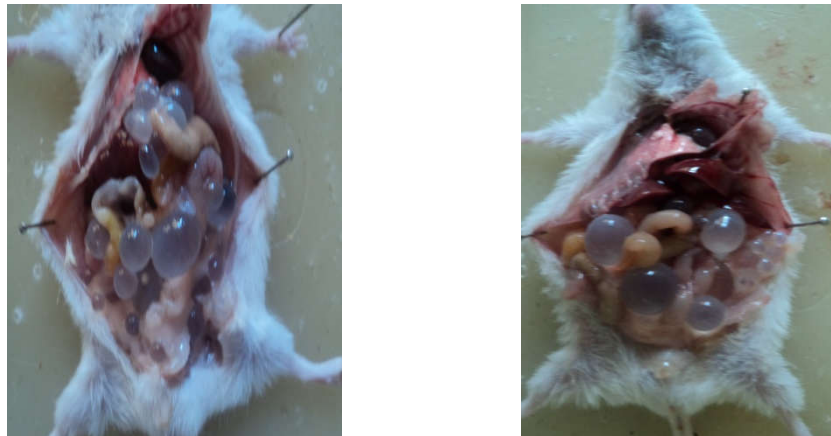Histopathological study

It included pathological and histological Studies. After anesthesia of mice with chloroform, kidney of the mice were visually inspected and dissected. Portions of kidney tissue and cysts in them were prepared for the histopathological study. Tissues were processed according to (2), briefly the tissue from the kidney collected and placed in 10% formalin for histopathological studies and dehydrated by several

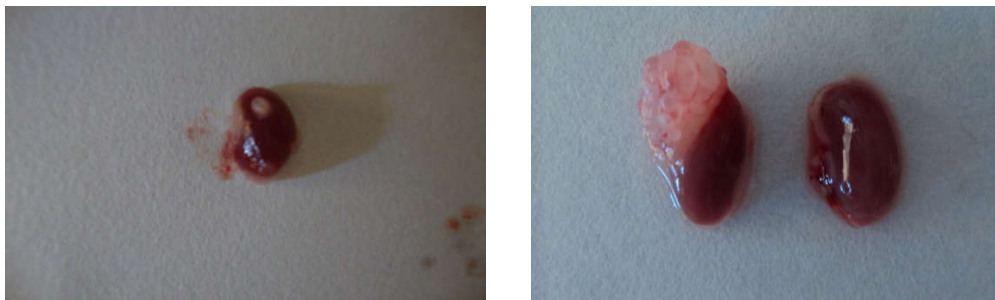
dilutions of ethanol alcohol dealcoholization with xylol, then embedded with paraffin wax blocked (3-5) mm thickness sections were obtained by microtome. The sections were put on glass slides deparaffinised with xylol, rehydrated by alcohol and stained by hematoxyline and eosin.

RESULTS

The examination of experimentally infected males Balb/c mice with protoscolices at 6 months – post infection revealed 11% of experimentally animals have hydatid cyst on kidney as well as presence of hydatid cyst in liver, spleen, mesenteries, and lungs .



Male of infected mice with hydatid cysts after six month- post infection



A

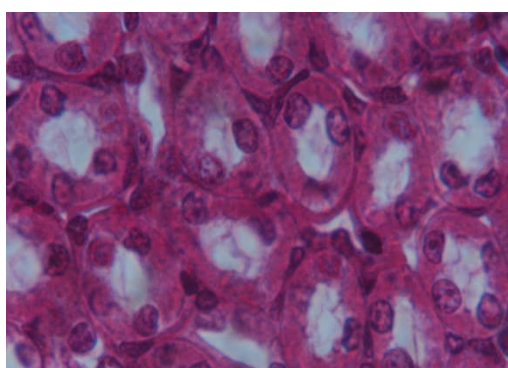
B

Kidney of infected mice with hydatid cysts after one (A) and six (B) month- post infection

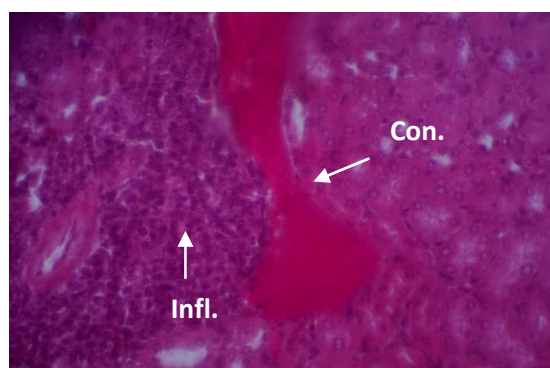
Blood urea test (BUN) for each of the infected and control group were investigated. The results showed increase in the level of blood urea (40. 5 μ g/ml) in the infected animals compared with 37.37 in the control group .

Groups	BUN $\mu\text{g/ml}$
Control group	37.37
Infected group	40.5

Granulation tissue, congestion, edema, peri-vascular inflammatory cell, fat necrosis in the adipose tissue and inflammation around tubules in the adjacent area were recorded after the examination of the kidney tissue six months after infection. Also, the results have shown increases in the focal inflammatory cell of the infected organs of the infected group compared to control group.



- A -

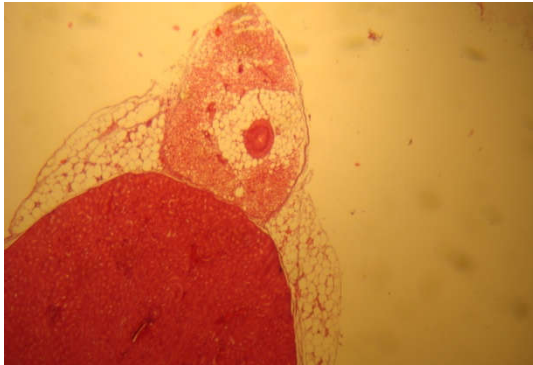


- B -

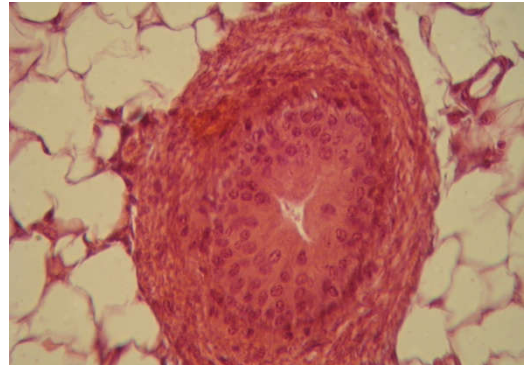
The kidney: A : before infection , B : After six month – post infection

The structure of the hydatid cyst was also examined in the present study and it was found that the hydatid cyst of *E. granulosus* consisted of three layers starting with the fibrous layer, the second layer of the cyst was the laminated layer and the germinal is the third (figures, C, D).

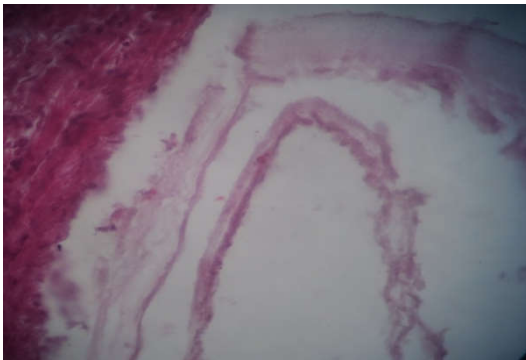
At initial infection of kidney superficially with hydatid cyst and in about one month, the protoscolex becomes with multilayer epithelial lining with prominent acidophilic cytoplasm (epithelial layer between 5-6 layer enclosed directly by fibrous capsule like, in the outside adipose tissue at the far exterior part. See the protoscolex was found in the perirenal region. 4X macro kidney & protoscolex in perirenal region (figure, A, B, E, F).



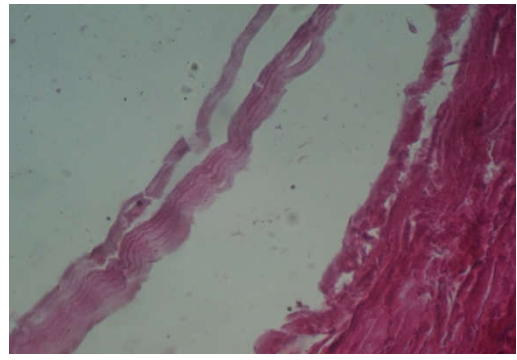
-A-



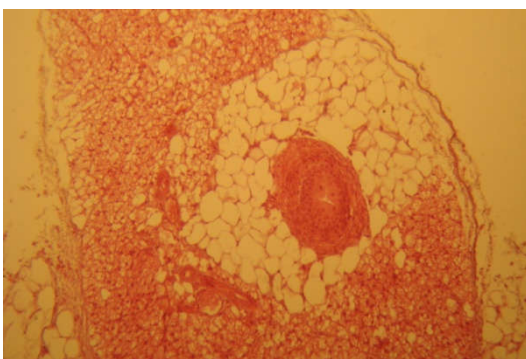
-B-



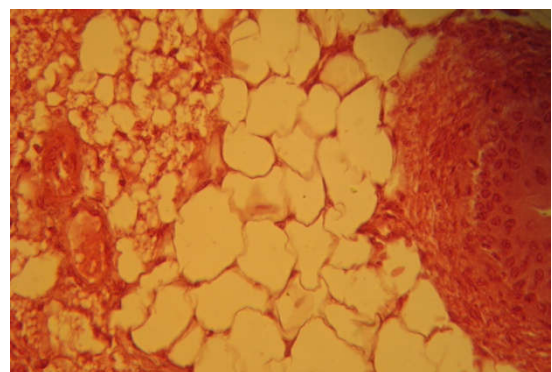
-C-



-D-



E



F

Figure A, B, E, F.: The protoscolex was found in the perirenal region. kidney And protoscolex in perirenal region. H&E,4X

DISCUSSION

In Iraq , the studies about the infection with hydatid cyst are huge (2,3, 4,5, and 6) but it is rarely discussed or deals with effect of the infection with hydatid cyst on kidneys structure and kidneys function .

The infection with hydatid cyst is primary from ingestion of egg after release with stool of dog or definitive host or secondary hydatid cyst which is produced from rupture of primary hydatid cyst (7,8) . the current study were designed from the second route of infection , therefore, kidneys were recorded about 11 % of total percent for infection with hydatid cyst but kidneys are rarely infected with primary hydatid cyst because liver and lung are mainly involved with primary hydatid cyst, further , if there is unsuitable condition in liver and lung the parasite will migrate to the other organ to form hydatid cyst like kidneys or may be brain .

Involvement of the kidney is rare (3% of cases). Renal HCs are usually located in the upper or lower pole. HCs are frequently solitary and located in the cortex, and they may reach 10 cm in diameter before any clinical symptoms are noted (16).

The tissues and cysts from kidney of each uninfected and infected animals were examined in the present study, The results have showed increases in the focal inflammatory cell of the infected organs of the infected group compared to control group . the number of lymphocytes and macrophages were increased in the tissues of organs infected with hydatid cysts (9).

The vascular congestion had been seen in infected organs and this corresponded with the study of 2, 12, 15.

The structure of the hydatid cyst was also examined in the present study and it was found that the hydatid cyst of *E. granulosus* consisted of three layers starting with the fibrous layer which were resulted from the stimulation of host tissues by hydatid cysts as a foreign body (12) . The second layer of the cyst was the laminated layer and the germinal is the third from which the protoscolex proliferated as recognized in the present study

REFERENCES

1. Akhan , O. ; Ensari , S. and Ozmen, M. (2002) . Percutaneous treatment of a period gland hydatid cyst . Eur. Radiol. , 12: 597-599.
2. Al – Humairy , A. KH. (2010). Evaluation of the Activity *Datura stramonium* Seeds Extracts on Growth and Development of Hydatid Cysts for *Echinococcus granulosus* in White Mice Balb/c (Therapeutic , Histologic and Immunologic Study).Ph. D. Thesis . College of Science , Kufa University.
3. Al – Mobarak, Z.A. (2006). Effect of peel extracts of *Punica* fruits on on echinococcosis of *Echinococcus granulosus* . M. Sc. Thesis, College of

- Education . , Kufa University **Dar, F.K. and Alkarmi ,T. (1997)**. Public health aspects of cystic echinococcosis in the Arab countries. *Acta. Tropica*. 67 : 125-132.
4. **Al-Saimary, I.E. and Zeki, A. (1999)**. *In vitro* chemotherapeutic effects of antibiotics and plant extract on protoscolices viability of human hydatid cysts. *J. Basrah Res.*, 20: 79-98.
 5. **Al-Saimary, I.E., Al-Shemari, M.N. and Al-Fayadh, M.M.A. (2010)**. Epidemiological and immunological findings on human Hydatidosis . *Medical Practice and Review* ., 1: 26-34.
 6. **Al-Sanafi, A. E. (1996)**. Possible new treatments for hepatic hydatid disease: Methotrexate and praziquantel. Ph. D. Thesis, College of Medicine , University of Baghdad: 107 pp.
 7. **Georgopoulos , S. ; Korres, S. ; Riga, M. and Ferekidis, E. (2007)**. Hydatid cyst in the bile duct of the submandibular gland. *Int. J. Oral. Surg.* , 36: 177 – 179.
 8. **John , D.T. and Petri , W.A. (2006)**. Markell and Voges' Medical parasitology . 9th ed. , Elsevier , United states of America : 468 pp.
 9. **Mendez-Sanchez, N. ; Vega, R. ; Cortes, R. ; Corona, R. ; Bahena, R. and Uribe, M. (2003)**. Hepatic *Echinococcus granulosus*. A case report. *Annals , hepatol.* , 2(2) : 99-100.
 10. **Parija, S.C. and Sheela, D. C. (1999)**. Current concepts in the diagnosis of cystic echinococcosis in humans and Livestocks and intestinal echinococcosis in canine hosts. *J. vet. Parasit.*, 13: 93-102.
 11. **Pedrosa , Saiz , Arrazola , Ferreiros and Pedrosa . (2000)** . HD: radiologic and pathologic features and complications. *RadioGraphics* . 20:795–817.
 12. **Rigano, R. ; Profumo, E. ; Bruschi, F. ; Carulli, G. ; Azzara, A. ; Ioppolo, S. ; Buttari, B. ; Ortona, E. ; Margutti, P. ; Teggi, A. and Siracusano, A. (2001)**. Modulation of human immune response by *Echinococcus granulosus* antigen B and its possible role in evading host defence. *Infect. Immunol.* , 69 (1): 288-269.
 13. **Schalm, O.W.; Jain, N.C. and Carrol, E.J. (1975)**. *Veterinary hematology*. Leo and Febiger, ed. Philadelphia. Pp: 152-140.
 14. **Smyth, J. D. (1964)**. The biology of hydatid organisms. *Adv. Parasitol.* , 2: 169-219.
 15. **Sida , L. A. (2005)**. Trails in treatment of secondary hydatid disease in laboratory mice . Ph.D. Thesis , College of Education , University of Baghdad .(In Arabic)
 16. **Tuzun and Hekimoglu . (2001)**. Various locations of cystic and alveolar HD: CT appearances. *J Comput Assist Tomogr* . 25:81–87.