

Clinical diagnosis of the first cases of extrapulmonary (GIT) COVID-19 in Thi-Qar, south of Iraq

Faez Khalaf MD¹, Minen Al-Kafajy, PhD¹, Ali Abdulbaqi Ali Ismael MD¹, Firas Abdullah Al-Baghdadi MD¹.

¹ College of Medicine, University of Thi-Qar, Iraq
Corresponding author: Minen Al-Kafajy, PhD¹, minan@utq.edu.iq

Abstract

An outburst of novel coronavirus (COVID-19) that began in Wuhan, China, has blowout speedily, with cases nowadays established in numerous nations. Although COVID-19 is utmost well-known for creating substantial respiratory signs, it can also result in numerous extrapulmonary appearances. These situations include thrombotic difficulties, myocardial dysfunction and arrhythmia, acute coronary illness, acute kidney and gastrointestinal indications, hepatocellular damage, high blood sugar and ketosis, neurologic illnesses, ocular symptoms, and dermatologic complications. In our research, we documented the first cases of COVID-2019 infection in the gastrointestinal tract (GIT) in Thi-Qar city, south of Iraq. We categorized the patient's initial mild symptoms of the disease course with expansion to extrapulmonary symptoms in about a week after the illness. We described the diagnosis and laboratory tests of the cases. From 130 COVID-19 positive cases, there was 110 cases has both pulmonary and digestive signs, while, only 20 has display digestive signs alone. Our positive cases have shown increased level of ferritin, D-dimer and IgM serum level. In conclusion, our data urge the importance of close collaboration between clinicians, laboratory scientist and government authorities, as well as the urgent need for rapid spreading of clinical statistics linked to the care of Iraqi patients with this evolving novel viral infection.

Keywords: extrapulmonary (GIT); COVID-19; Thi-Qar; Iraq

INTRODUCTION

December 2019, in Wuhan city (China), numerous cases of pneumonia of mysterious etiology have been documented ¹. Respiratory droplets and contact routes are the main ways to spread COVID-19 ².

Employing phylogenetic examination, team of scientists have classified SARS-CoV-2 proteins into three groups A, B, and C depending on the amino acids' central variants sequencing. The team detected substantial percentage of B type present in East Asia, whereas A and C are the highest communal type among Caucasian humans in Europe and America ³.

Researches and physicians widely believe that respiratory signs such as high temperature, loss in taste and smell, dry cough, and even dyspnea imply the most common indexes of COVID-19, which is determinedly transmitted via droplets and contact transmission. However, the occurrence of less mutual features like loss stool, nausea, unsettled stomach, and abdominal discomfort varies significantly among different populations, along with an early and insignificant fever followed by typical respiratory symptoms ⁴.

Developing statistics propose that the gastrointestinal tract and liver might also be affected by SARS-CoV-2, on the basis that gastrointestinal epithelial and liver cells prompt the angiotensin-converting enzyme 2 (ACE2), the vital receptor of COVID-19. Meanwhile ACE2 is found in multiple extrapulmonary tissues, viral tissue harm is a plausible machine of sickness in others organs than the lung. Furthermore, endothelial injury and thrombo-injury, unequal immune responses, and maladaptation of ACE2-connected pathways might all participate to these extrapulmonary

manifestations of the disease ⁵.

Non pulmonary COVID-19 infection confirmed in the United States documented nausea and vomiting on the first two days at the hospitals, and then produced a movable stool on the second day. The viral nucleic acids were noticed in both of the loose feces and the respiratory sputum ⁶.

204 patients having COVID-19 were analyzed by independent researchers using laboratory test, imaging, and historical data and found that 103 patients (50%) reported digestive symptoms, such as the absence of appetite, loss stool, vomiting, and digestive tract pain. Although, most patients have shown fever or respiratory symptoms, for six patients, only extra-pulmonary symptoms were present during the whole progression of the disease ⁷.

On the other hand, Heat and ultraviolet rays are two means approaches to weaken Coronaviruses. The virus could be inactivated at 56 °C for 30 min if it bare to heat or UV. On contrast, they can be kept for numerous years at -80 °C. Furthermore, using either diluted chlorine or 75% ethanol can competently restrict COVID-19 ⁸.

Finally, our research focused on the extrapulmonary organ-specific pathophysiology, manifestation and management decisions for COVID-19 patients to support physician and scientists in identifying and monitoring the variety of the disease signs. Our long-term goal is to developing novel therapeutic strategies for all infected organs.

MATERIALS AND METHODS

Clinical examination: assessment of 130 patients' temperature, blood pressure, blood oxygen level has been

Clinical diagnosis of the first cases of extrapulmonary (GIT) COVID-19 in Thi-Qar, south of Iraq

done for every patient with extra precaution by wearing personal protective equipment (PPE).

CT scan and angiography: 130 Chest radiography was performed using CT machine by radiologist.

Serum, nasopharyngeal and oropharyngeal swabs: 130 Specimens were collected in accordance with Iraqi ministry of health guidelines and world health organization (WHO). The samples included serum and nasopharyngeal and oropharyngeal swab samples. Later, the specimens were gathered, and the patient was cleared to home quarantine with active 24-hour care by the government health authority.

Molecular biology tests: 130 nasopharyngeal swab specimens were obtained and sent for detection of viral respiratory pathogens by qPCR; including influenza A and B, parainfluenza, respiratory syncytial virus, rhinovirus, adenovirus, and common coronavirus strain known to cause illness in humans (COVID-19). This assessment was repeated again within 48 hours. The PCR method has been done as it described in⁹.

Serum ferritin: 130 Serum were collected from all the patients to detect the level of ferritin. Adults normal value Male 30-400 ng/ml and female 15-150 ng/ml.

D-Dimmer assay: 130 specimens have been tested using Fluorescence immunoassay technology. The normal value should be less than 500 ng/dl.

Complete blood picture: 130 blood samples have been performed using minray instrument.

C-reactive protein: 130 serum have been tested for C-reactive protein. Normal value less than 5 mg/L.


Immunological tests: IgG and IgM serum COVID test has been done.

Statistical analysis: GraphPad prism 8 has been used to analyze the data.

RESULTS

On admission, 110 the patients were reported insistent dry cough and a three-day history of nausea and vomiting (table 1). No shortness of breath or chest burn had been detected. dynamic signs were within normal varieties. On physical examination, the 110 patients were found to have dry mucous membranes, while 20 have only extra-pulmonary signs Figure (1).

Total number of Patients



Total=130

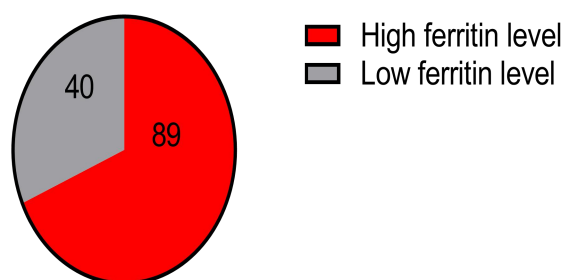
Figure 1. Show number of patients

73 patients had digestive symptoms that were existing throughout the entire course of illness. The features of gastrointestinal symptoms in COVID-19 are more insidious than the respiratory symptoms, making them easy to overlook. Though, 20 patients have only gastrointestinal symptoms during the whole course of the disease, and some continue to shed the virus in feces, despite respiratory samples testing negative. Further study is obligatory to determine whether these patients represent a potentially unheeded means of transmission of COVID-19.

High temperature over 105° F were common between all the 130 cases that included in the study.

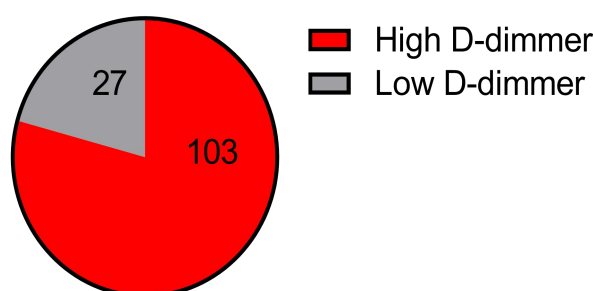
Serum ferritin is a vital mediator of immune dysregulation. We found that 89 patients had elevated ferritin level. While 103 patients had D-Dimmer level exceed the normal level Figure 2.

COVID Patients



Total=130

COVID Patients



Total=130

Figure 2. Show patients of Covid-19 with ferritin & Di-dimmer.

Chest radiography: the results reported that the disease has progressed in 110 patients to show pulmonary symptoms. While, 20 patients had shown no abnormalities in the chest

Table1. The percentages of COVID-19 symptoms in patients that primarily has GIT infection

Abdominal discomfort	75%
Nausea	90%
Puking	56%
Liquid stool	40%
Anorexia	90%

Polymerase chain reaction (PCR), C-reactive protein and immunological tests:

90 patient's serum were tested positive using PCR test. C-reactive protein was elevated in all the cases. On the other hand, COVID-19 IgG was detected in 20 patients, while IgM was present in 105 cases.

DISCUSSION

Evidence of person-to-person transmission has been published. The presence of 110 patient that had digestive symptoms followed by pulmonary symptoms were consistent with other publication outside Iraq⁶.

Clinical diagnosis of the first cases of extrapulmonary (GIT) COVID-19 in Thi-Qar, south of Iraq

89 patients that showed hyper-ferritinemia have been expected as the elevated ferritin level is linked to dysregulation in immunity as it is disturbing cytokines function¹⁰.

Our data has shown 103 patients presented with elevated D-dimer. Our results are reasonable as the D-dimer is a deprivation creation of crosslinked fibrin subsequent from plasmin division.

Chest CT has documented the presence of bilateral lower lobe back ground glass appearance in most cases which indicate the presence of COVID-19.

PCR has been performed and 90 cases only showed positive results. We elucidated these results as PCR is sensitive method so probably the RNA level has not reached the concentration require to be detected in the other cases that showed negative results. The negative PCR results for 20 digestive COVID-19 patients are accepted as those cohort have not shown any respiratory syndrome.

Finally, the rapid test of IgG and IgM has given positive for a total of 125 patients distributed as 20 for IgG and 105 for IgM. In general IgG represent an old infection while IgM

represent a new infection. As COVID-19 is a new disease that spread recently in Iraq so its accepted as IgM is more than IgG. Although, the rapid test is not dependable method as it not recommended by the WHO.

CONCLUSION

Our data has shown the presence of COVID-19 infection in the GIT alone, and by this, we are the first to report it in the city. Other patients have shown combined digestive and pulmonary signs. In our research, we focused on the extrapulmonary organ-specific pathophysiology, manifestation and management decisions for COVID-19 patients to support physician and scientists in identifying and monitoring the variety of manifestations, and in developing novel therapeutic strategies for all organ systems that could be infected.

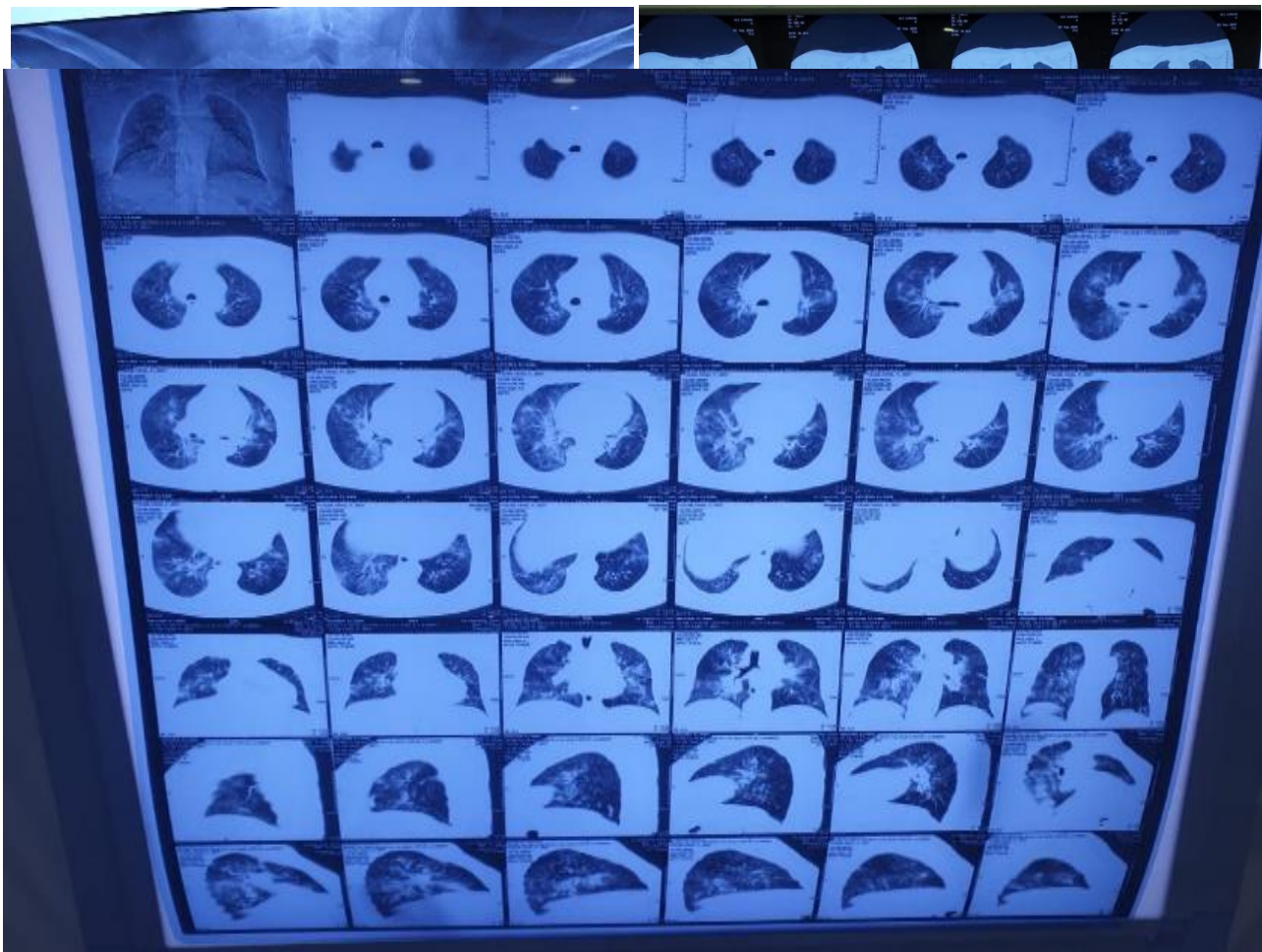Future direction:

We would like to investigate how COVID-19 could affect breast cancer women in Iraq⁹, and for hepatitis patients¹⁰.

APPENDIX:

Patients Lung X-ray and CT scan

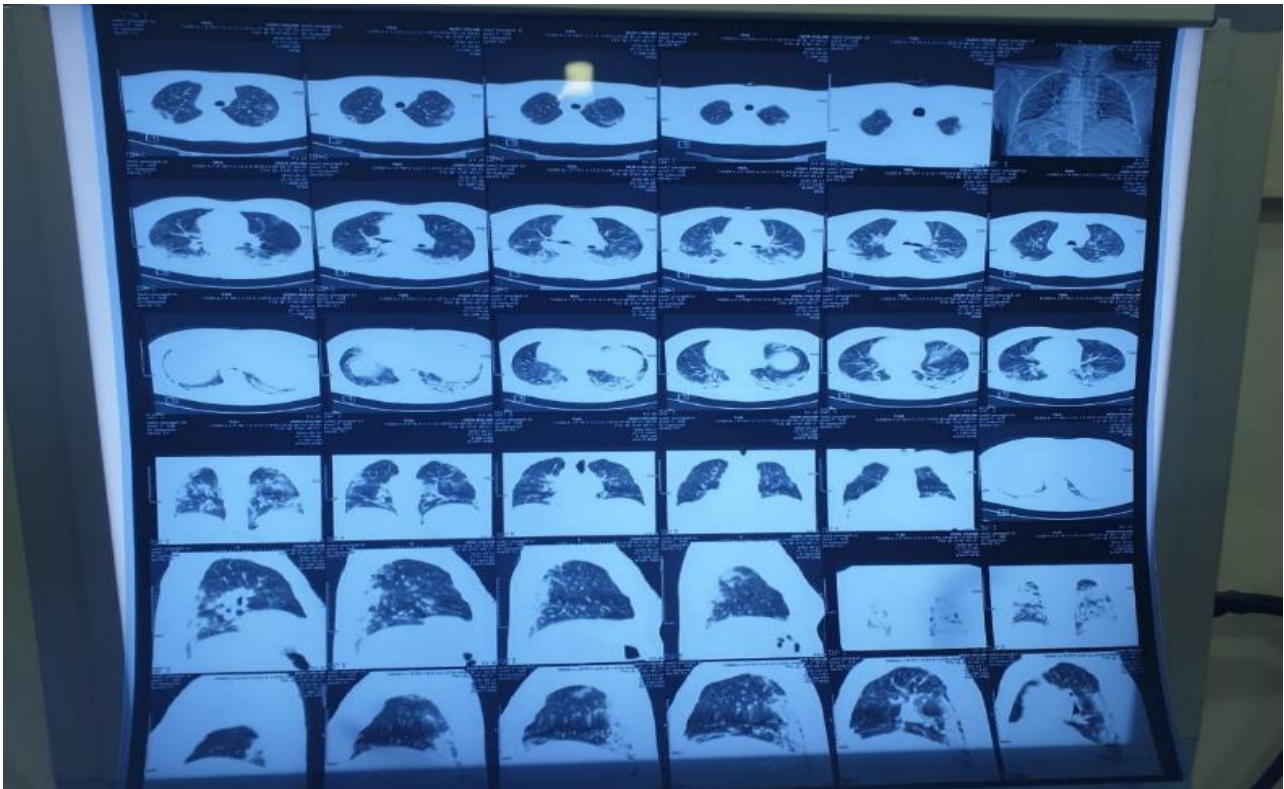
1. 50 years old female attended our private clinic has shown few peripheral ground glass densities in the right lower lobe suspicious of COVID-19 for further assessment



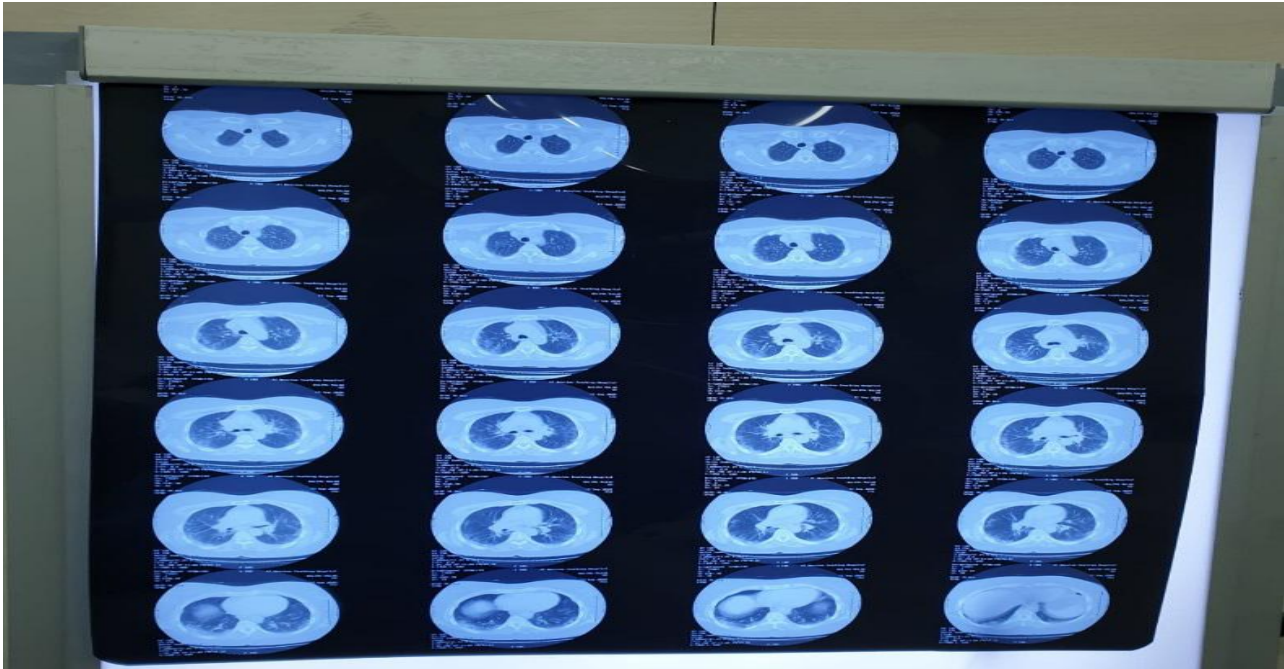
2. Female patients in her fifties has shown bilateral basal peripheral multiple ground glass opacities involved both lungs. These finding suggested that there is a chance this patient has COVID-19

Clinical diagnosis of the first cases of extrapulmonary (GIT) COVID-19 in Thi-Qar, south of Iraq

3. 45 years Male has shown 50% probability to be infected by COVID-19 since bilateral basal peripheral multiple ground glass opacities involved both lungs has been detected by CT scan



4. 47-year-old female has shown few peripheral ground glass densities in both lungs. These data led us to think that the patients infected with COVID-19



REFERENCES

1. Wu, Fan, Su Zhao, Bin Yu, Yan-Mei Chen, Wen Wang, Zhi-Gang Song, Yi Hu, Zhao-Wu Tao, Jun-Hua Tian, and Yuan-Yuan Pei. "A New Coronavirus Associated with Human Respiratory Disease in China." *Nature*.2020; 579 (7798): 265–69.
2. Liu, Jiaye, Xuejiao Liao, Shen Qian, Jing Yuan, Fuxiang Wang, Yingxia Liu, Zhaoqin Wang, Fu-Sheng Wang, Lei Liu, and Zheng Zhang. "Community Transmission of Severe Acute Respiratory Syndrome Coronavirus 2, Shenzhen, China, 2020." *Emerging Infectious Diseases*.2020; 26 (6).
3. Forster, Peter, Lucy Forster, Colin Renfrew, and Michael Forster. "Phylogenetic Network Analysis of SARS-CoV-2 Genomes." *Proceedings of the National Academy of Sciences*, April.2020; 202004999. <https://doi.org/10.1073/pnas.2004999117>.

Clinical diagnosis of the first cases of extrapulmonary (GIT) COVID-19 in Thi-Qar, south of Iraq

4. Qi, Furong, Shen Qian, Shuye Zhang, and Zheng Zhang. "Single Cell RNA Sequencing of 13 Human Tissues Identify Cell Types and Receptors of Human Coronaviruses." *Biochemical and Biophysical Research Communications*, 2020.
5. Holshue, Michelle L, Chas DeBolt, Scott Lindquist, Kathy H Lofy, John Wiesman, Hollianne Bruce, Christopher Spitters, Keith Ericson, Sara Wilkerson, and Ahmet Tural. 2020. "First Case of 2019 Novel Coronavirus in the United States." *New England Journal of Medicine*, 2020.
6. Pan, Lei, Mi Mu, Pengcheng Yang, Yu Sun, Runsheng Wang, Junhong Yan, Pibao Li, Baoguang Hu, Jing Wang, and Chao Hu. "Clinical Characteristics of COVID-19 Patients with Digestive Symptoms in Hubei, China: A Descriptive, Cross-Sectional, Multicenter Study." *The American Journal of Gastroenterology* 115, 2020.
7. Zhou, Peng, Xing-Lou Yang, Xian-Guang Wang, Ben Hu, Lei Zhang, Wei Zhang, Hao-Rui Si, Yan Zhu, Bei Li, and Chao-Lin Huang. "A Pneumonia Outbreak Associated with a New Coronavirus of Probable Bat Origin." *Nature*. 2020; 579 (7798): 270–73.
8. Al-Kafajy, Minen. "Breast Cancer Risk Trends of Iraqi Women." *Medico Legal Update*. 2020; 20 (1): 383–86.
9. Al-Kafajy, Minen. "Identifying the Correlation between the Incidence of Breast Cancer and Hepatitis B Virus of Iraqi Women." *Indian Journal of Forensic Medicine & Toxicology* .2020; 14 (2): 2250–55.
10. Al-Kafajy, Minen. "Polymerase Chain Reaction Is a Precise Method to Reveal and Diagnosis of Hepatitis B for Iraqi Patients." *International Journal of Pharmaceutical Research*. 2020; 12(1). <https://doi.org/10.31838/ijpr/2020.12.02.0160>.
11. Terpos, Evangelos, Ioannis Ntanas-Stathopoulos, Ismail Elalamy, Efstathios Kastritis, Theodoros N. Sergentanis, Marianna Politou, Theodora Psaltopoulou, Grigoris Gerotziapas, and Meletios A. Dimopoulos. "Hematological Findings and Complications of COVID-19." *American Journal of Hematology*. 2020; 95 (7): 834–47. <https://doi.org/10.1002/ajh.25829>.
12. Wang, Dawei, Bo Hu, Chang Hu, Fangfang Zhu, Xing Liu, Jing Zhang, Binbin Wang, Hui Xiang, Zhenshun Cheng, and Yong Xiong. "Clinical Characteristics of 138 Hospitalized Patients with 2019 Novel Coronavirus-Infected Pneumonia in Wuhan, China." *Jama*. 2020; 323 (11): 1061–69.