

**IN VITRO AND IN VIVO ACTIVITY OF (2- deca - 3,d- dienyloxy) CARBONYL
BENZEIC ACID EXTRACTED FROM *Cladophora crispata* AGAINST THE
SPLEENIC HYDATID CYST**

AMAL KH. KHALAF*

MAJEED SALEH. K**

AHMED A.NASIR AIAMAIRY***

AL-SEREAH BAHAA. A****

*Dept. of Microbiology, College of Medicine, University of Thi-qar, Iraq

** 55 Desborough Road, Hartford- Huntingdom, Cambridgeshire, PE 29 1 SN, England

***Cancer Research Unit, College of Medicine, University of Thi-qar, Iraq

****Dept. of Pathology& Poultry diseases, College of Veterinary Medicine, University of Basrah,Basrah, Iraq

ABSTRACT

The aim of the present study is testing the activity of (2- deca - 3, d- dienyloxy) carbonyl benzeic acid extracted from *Cladophora crispata* against the hydatid cyst of *Echinococcus granulosus*. The extracted bioactive compounds were identified by using GC- Mass technique. the results was found that the compound of the methanol extract of *C. crispata* is more active by it is explain *in vitro* and *in vivo* activity against the protoscolices of hydatid cyst where the protoscolices are killed after three days – post treatment in concentrations 300 µg/ml followed by 200 µg/ml that explain activity after five days - post treatment.

KEYWORDS: Carbonyl Benzeic Acid, Hydatid Cyst &Spleen

INTRODUCTION

Hydatid disease, hydatidosis, cystic echinococcosis, unilocular hydatid disease, *E. granulosus* Echinococcosis, and Al - akyas al-mai'yah' and 'al atash' all terms describing infections which are caused by cestodes of the genus *Echinococcus* particularly *E. granulosus* [1]. The hydatid cyst remains a significant public health hazard in endemic areas such as Iraq, Turkey, the Middle East, South America, New Zealand, Africa, China, northern Kenya, Australia, and other sheep-raising areas [2]. As an endemic disease, it causes social and economic losses for countries. WHO reports stated that approximately 100,000 people in the world are infected with this disease every year which is common in rural populations of underdeveloped countries because of their close association with domestic and wild animals [3]. Until recent decades, surgery was the only option for the treatment of echinococcal cysts, however, chemotherapy with benzimidazole compounds and, more recently, cyst puncture, and percutaneous aspiration, injection of chemicals, and reaspiration (PAIR) are increasingly

seen to supplement or even replace surgery as the preferred treatment [4]. The undesirable side effects associated with this classical drug, as well as the development of resistance, are encouraging research into alternative synthetic or natural compounds which have high efficiency in treating hydatid disease. In this regard, most studies have focused on the activity of natural substances derived from higher plants, mainly due to their accessibility and use in traditional medicine. The treatment of the hydatid disease with plant extracts has been practiced for many centuries [5, 6, 7, 8, 9 & 10].

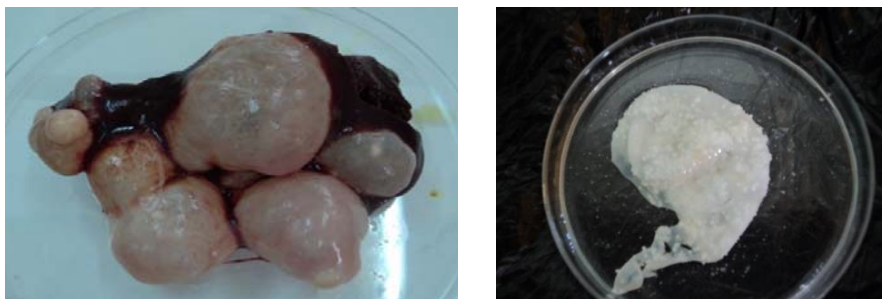MATERIALS AND METHODS

1. Parasite Materials, Protoscolices Preparation & IP injection of mice:

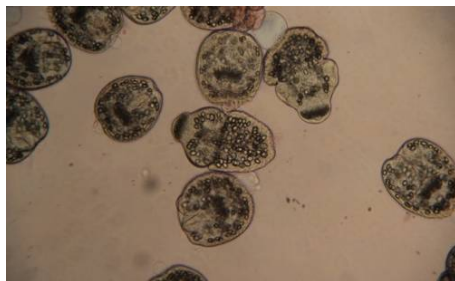
Fresh hydatid cysts were obtained from livers and lungs of naturally-infected sheep, which had been slaughtered at local abattoirs in Nassiriyah city, south of Iraq. They were wrapped carefully in clean plastic bags, placed in an ice box, and transported lab of microbiology, College of medicine, Thi-qar University, where protoscolices were isolated according to [11] method. The viability of protoscoleces were assessed by microscopic observation. Stained protoscoleces were considered as nonviable and the protoscoleces, which had not stained with eosin, were considered as viable according to conventional. Protoscolices were counted according to method [10]. The viable protoscolices were counted in 1ml based on the formula

Viability in 1 ml = number of protoscolices in (10 μ l) \times 100

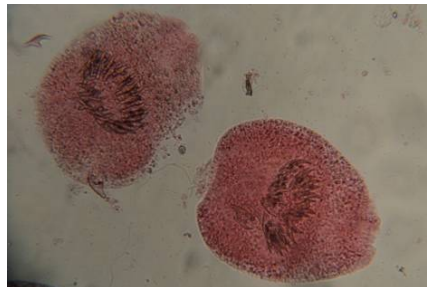
Eight male of *Mus musculus* mice Balb\C strain were injected with 0.2 ml 480/ ml (2400/5ml rate of viability) of protoscolices intraperitoneally and consider as positive group and left for six months. also, negative control group were included in the study and involve eight of uninfected male mice.



Hydatid cysts and germinal layer after removal from liver



Viable protoscolices



Non - viable protoscolices

2-Preparation of methanol extract and Design *in vitro*, *in vivo* experiment:

The methanol extracts to be prepared; dry mass in ratio (1:15g/ml) was extracted using magnetic stirrer through 24 hours. The precipitates were removed by filtration and left to dry until use, and then the filtrates were concentrated at room temperature. The effect of bioactive chemical compounds were studied *in vitro* compared with albendazole after determination of viability of protoscolices, lethal concentrations were chosen from LD₅₀ based on [12] method., *In vitro* study was designed as the following :

1. Three concentrations from methanol extract and three concentrations of albendazole, each of them were added alone to test tube containing 4 ml of Krebs ^o s ringer maintain medium.
2. The suspension of protoscolices were shaken and added to test tubes containing bioactive chemical compound in volume of 1 ml for each tube, approximately 2000-2500 of protoscolex based on the viability counting.
3. Control group was prepared with each experiment and include a test tube containing hydatid cyst fluid (Krebs ^o s ringer mention medium + hydatid sand, 4:1) with the same viability.
4. The viability of protoscolices was observed from the first hour continuously for seven days and repeatedly three times for each concentration to calculate the mean of viable protoscolex. Then after, each infected mice with hydatid cyst after six months – post infection were treated with three doses (100, 200, 300 µg/ml) that is derived from LD₅₀.

3- Histopathology:

It included pathological and histological Studies. After anesthesia of mice with chloroform, spleen of the mice were visually inspected and dissected. Portions of spleen tissue and cysts in them were prepared for the histopathological study. Tissues were processed according [13], briefly the tissue from the spleen collected and placed in 10% formalin for histopathological studies and dehydrated by several dilutions of ethanol alcohol dealcoholization with xylol, then embedded with paraffin wax blocked (3-5) mm thickness sections were obtained by microtome. The sections were put on glass slides deparaffinised with xylol, rehydrated by alcohol and stained by hematoxyline and eosin.

4 - GC-Mass spectra analysis:

GC-Mass spectra of fraction was done in Bruker company, Iran and Al- Elbait university in Jordin.

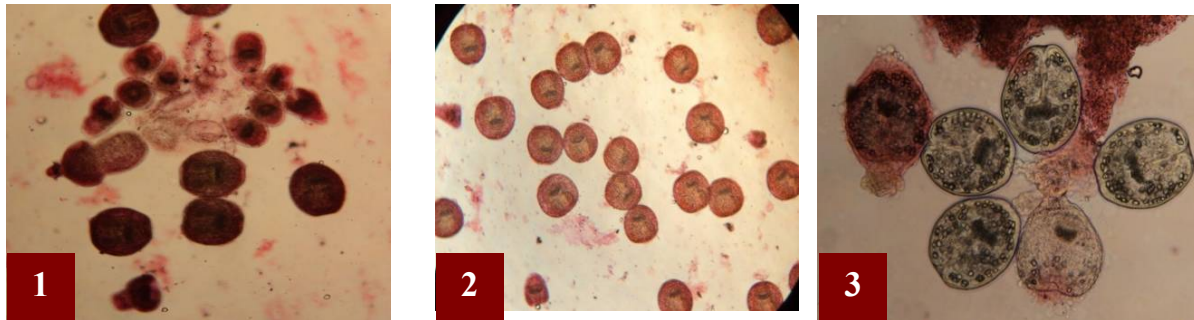
RESULTS

In vitro activity:

Methanol extract of *Cladophora crispata* recorded high activity at 300 µg/ml after three days - post treatment, while 100 µg/ml and 200 µg/ml has activity after five days – post treatment since the protoscolices still viable after four days – post treatment recording 6.6 and 3.3 mean of viability. Further the activity of methanol extract are seen through the first hour on the protoscolices compared with control one, see the following table :

Table (1): Viability of protoscolices treated with methanol extract of *C. crispata*

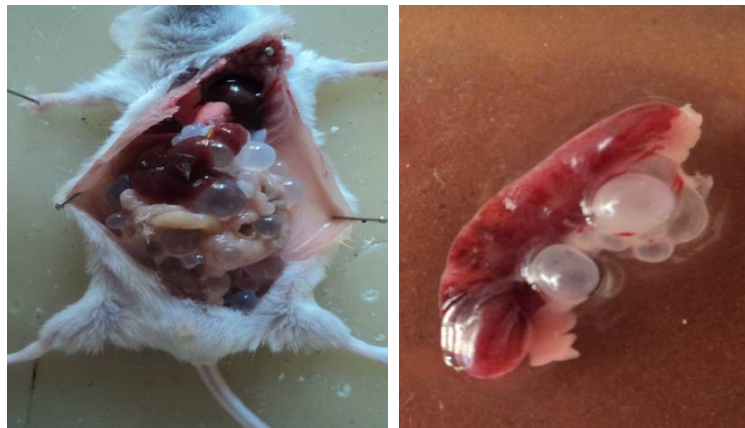Concentration\ time of treatment	Mean of viability								
	1 h	4 h	1 day	2 days	3 days	4 days	5 days	6 days	7days
100 µg/ml	80.33	60.33	42	31.66	20	13.66	6.66	0	0
200	76.33	55	38.66	26.33	15.66	9.33	3.33	0	0
300	69.33	50.33	31.66	22.33	10	0	0	0	0
Control	95.66	92.66	90.2	88.33	80.66	71.66	69.33	61.66	58.33
L.S.D.	0.94								
Significant differences, $P \leq 0.05$									



Pictures of treated protoscolices where :
3, control group (viable protoscolices).
1,2, protoscolices treated methanol extract of *C. crispata*.

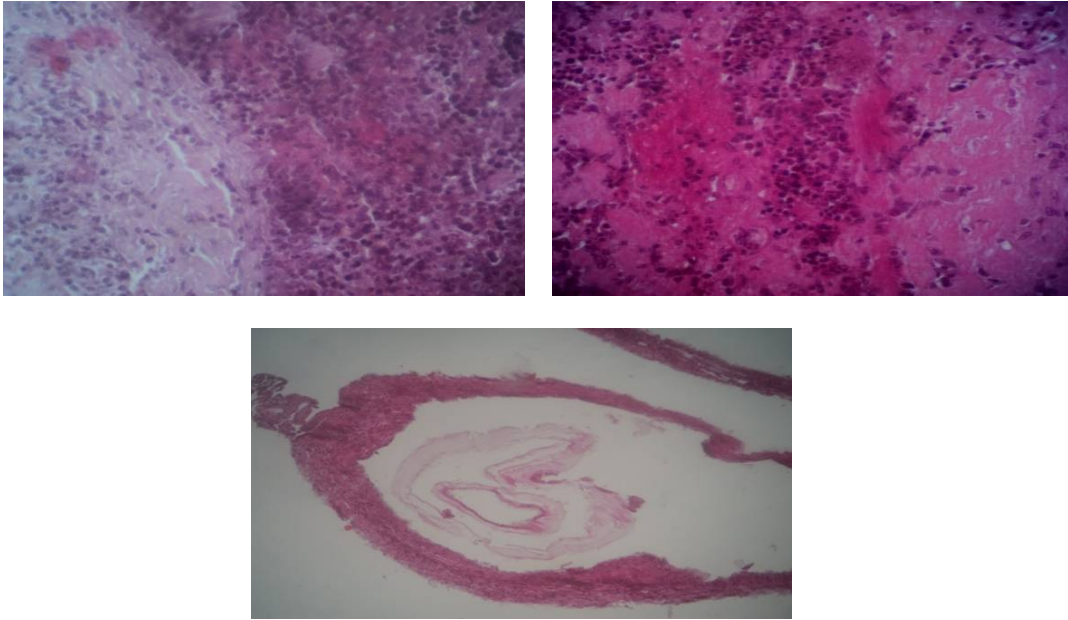
- ***In vivo* activity :**

The examination of experimentally infected males Balb/c mice with protoscolices at 6 months – post infection revealed that the experimentally animals have hydatid cyst on spleen as well as presence of hydatid cyst in liver, kidneys, mesenteries, and lungs, see the following pictures.



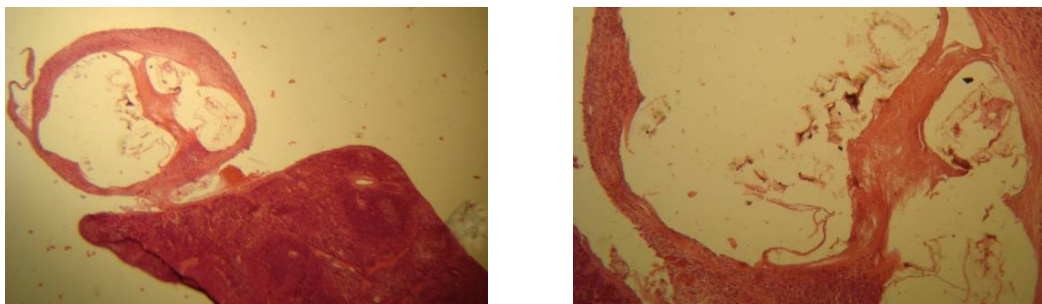
Infected mice and spleen with hydatid cyst

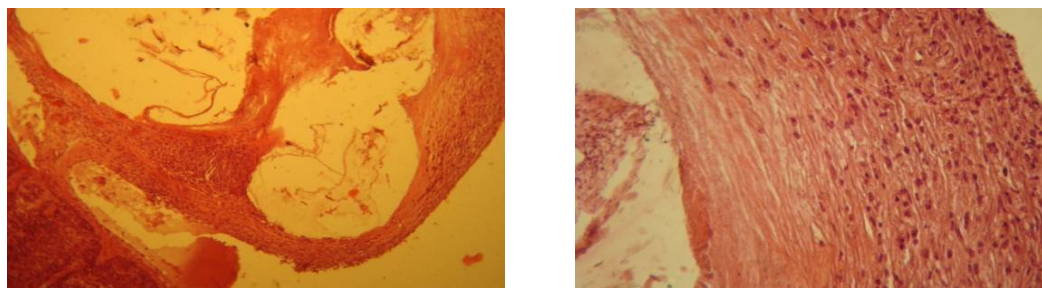
The histological examination of the spleen at the 6th months – post infection revealed a poor lymphoid tissue in white pulp and severe changes in red pulp represented by congestion, edema, and focal inflammatory cells that belonged to lymphocyte, plasma cells and macrophages. The structure of the hydatid cyst was also examined in the present study and it was found that the hydatid cyst of *E. granulosus* consisted of three layers starting with the fibrous layer, The second layer of the cyst was the laminated layer and the germinal is the third from which the protoscolex proliferated as recognized in the present study.



Pictures of infected spleen

Treatment for the infected mice with methanol extract indicates that the spleen has a prominent red pulp and the white pulp has low atrophy in the lymphoid tissue. The third dose of extract had showed an activity during the destruction and separation of the germinal layer of hydatid cysts with its content from laminated layer which is attached to the fibrous layer in the spleen where spleen cells seemed to be normal.





Pictures of treated spleen

GC – Mass analysis of Extracts:

The methanolic, of *C. crispata* were subjected to GC – Mass spectroscopy analysis as follow

- Methanol extract of *C. crispata* :

GC – Mass spectrum (Fig, 1) of the methanol extract has recorded 22 peaks, (2- deca - 3,d- dienyloxy) carbonyl benzeoic acid consisted of 22.57% (R.T. 22.647) of the total extract followed by ethyl linoleolate (13.13% and 25.946 min of R.T.), and other compounds were tabled below :

Table (2) :Bioactive chemical compounds of methanol extract of *C. crispata*

Peak	R.T.	% of total	Compound	M.W.
1	20.264	3.26	- Phytol	298
2	22.647	22.57	- (2- deca - 3,d- dienyloxy) carbonyl benzeoic acid	302
3	25.946	13.13	- Ethyl linoleolate	293
4	32.411	1.65	- Diterpine	286.45

Acquired : 3 Jul 2011 20:17 using AcqMethod alkaloid.M
Instrument : online
Sample Name :
Misc Info :
Vial Number: 1

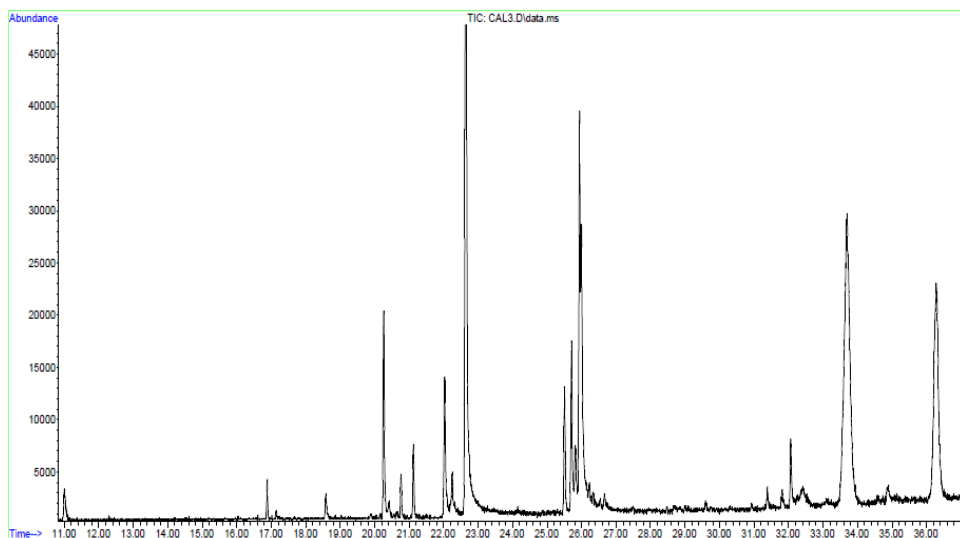
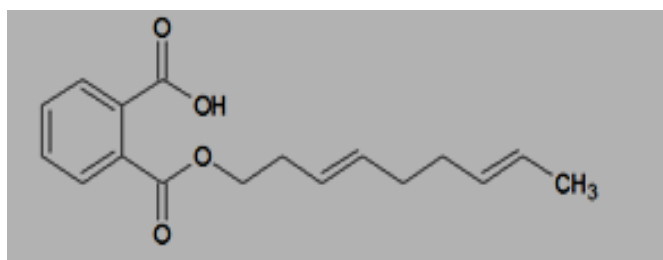


Figure (1) : GC spectrum of methanol extract of *C. crispata*



(2- deca - 3,d- dienyloxy) carbonyl benzeoic acid

DISCUSSION

Natural products have been the source of therapies since the advent of traditional medicine and healing; it remains a dominant source to date. The World Health Organization (WHO) estimates that 80% of the world's inhabitants depend mainly on traditional medicine for their primary health care [14]. The biochemical medicinal activity of natural products results from inhibition of enzymes action by interaction with thymol group (Sh) of enzymes and linking with DNA & RND, then destruction of these nucleic acids and finally inhibition the biosynthesis of cell proteins, metabolism of each of carbohydrates, and lipids .

Three concentrations of the methanol extract of *C. crispata* were used in the present study and only one concentration had an *in vitro* activity against the protoscolices of the hydatid

cyst after three days – post treatment but the other two concentrations showed activity after five days – post treatment. This means that the time plays an important role in the treatment since the decreased concentration leads to increase the time of treatment. The activity of the methanol extract could be explained by the presence of the compound (2-deca -3,d-dienyloxy) carbonyl benzeic acid. It is difficult to speculate the mechanism by which these bioactive compounds act as parasitocidal agents. In this regard [15] suggested that many bioactive chemical compounds exhibited their parasitocidal activity by virtue of their interference with the redox balance of the parasites, acting either on the respiratory chain or the cellular defenses against oxidative stress. It is also known that some bioactive compounds act by binding with the DNA of the parasite. For example, dihydroorotate dehydrogenase (DHOD), the fourth enzyme in the *de novo* pyrimidine biosynthetic pathway, is essential to parasites, including the electron acceptor capacity and cellular localization [16]. In this way, it has been recently demonstrated that the methanol extracts of brown algae *Ishige okamurae*, *Fucus evanescens*, and *Pelvetia babingtonii* contain potent noncompetitive inhibitors against *Trypanosoma cruzi* DHOD [16&14].

REFERENCES

1. Dar, F.K. and Alkarmi,T. (1997). Public health aspects of cystic echinococcosis in the Arab countries. *Acta. Tropica*. 67 : 125-132.
2. Tiaoying, L. ; Jiamin, Q. ; Wen, Y. ; Craig, P.S. ; Xingwang, C. and Schantz, O.M. (2005). Echinococcosis in Tibetan populations, western Sichuan province, china. *Emerg. Infect. Dis.*, 11 : 1866 – 1873.
3. Parija, S.C. and Sheela, D. C. (1999). Current concepts in the diagnosis of cystic echinococcosis in humans and Livestocks and intestinal echinococcosis in canine hosts. *J. vet. Parasit.*, 13: 93-102.
4. Akhan, O. ; Ensari, S. and Ozmen, M. (2002). Precutaneous treatment of a period gland hydatid cyst. *Eur. Radiol.*, 12: 597-599.
5. Al-Rubaei, S.S.M. (1999). Effect of some plant extracts on the inhibition of *Echinococcus granulosus* protoscolices *in vitro* and *in vivo*. M.Sc. Thesis, Baghdad University.
6. Al-Saimary, I.E. and Zeki, A. (1999). *In vitro* chemotherapeutic effects of antibiotics and plant extract on protoscolices viability of human hydatid cysts. *J. Basrah Res.*, 20: 79-98.
7. Al – Mobarak, Z.A. (2006). Effect of peel extracts of *Punica* fruits on on echinococcosis of *Echinococcus granulosus*. M. Sc. Thesis, College of Education. Kufa University, (In Arabic).
8. Mezher, A.H. ; Majed, M. and Kadhim, W. (2008). Effect of *Piganum harmala* on viability of protoscolices *in vitro*. *J. Karbala. Sci.*, 12: 23- 31.
9. Barzinji,A.K.R. ;Mothana, R.A. and Nasher, A.K. (2009). Effect of leaf extracts of *Dendrosicyos socotrana* and *Jatropha unicosata* on the viability of *Echinococcus granulosus* protoscolices. *Eur. Asia.J. Bio. Sci.* 3: 122-129.
10. Al – Humairy, A. KH. (2010). Evaluation of the Activity *Datura stramonium* Seeds Extracts on Growth and Development of Hydatid Cysts for *Echinococcus granulosus* in White Mice Balb/c (Therapeutic, Histologic and Immunologic Study).Ph. D. Thesis. College of Science, Kufa University.
11. Smyth, J. D. (1964). The biology of hydatid organisms. *Adv. Parasitol.*, 2: 169-219.
12. Litchfield, J. T. and Wilcoxon, F. (1949). A simplified method of evaluating dose effect experiments. *J. pharmacol. EXP. and Therap.*, 96: 94-113.

13. Humanson, G. L. (1972). Animal tissue techniques. 3rd ed., W. H. Freeman and Company, San Fransisco, USA.
14. Taran,M.; Azizi,E.; Shikhvaisi, A. and Asadi, N.(2009). The Anthelmintic Effect of *Pistacia khinjuk* Against Protoscoleces of *Echinococcus granulosus*. World J. Zoo., 4: 291-295.
15. Sepulveda-Boza, S. and Cassels, BK. (1996): Plant metabolites active against *Trypanosoma cruzi*. *Planta Med* 62: 98–105.
16. Nara, T.; Kamei, Y.; Tsubouchi, A.; Annoura, T.; Hirota, K.; Lizumi, K. Dohmoto, Y. and Aoki T.(2000). Inhibitory action of marine algae extracts on the *Trypanosoma cruzi* dihydroorotate dehydrogenase activity and on the protozoan growth in mammalian cells. *Parasitol. Int.* 54: 59–64.