



INTERNATIONAL JOURNAL OF RESEARCH IN PHARMACEUTICAL SCIENCES

Published by Pharmascope Publications

Journal Home Page: www.pharmascope.org/ijrps

Molluscum Contagiosum in Iraqi Patients

Alaa Naif^{*1}, Yahya Ali², Hazim Yaseen², Bassam Hassan³¹Department of Dermatology, College of medicine, Thi-Qar University, Iraq²Al-Hussain teaching hospital, Thi-Qar Province, Iraq³Bent Al-Huda teaching hospital, Thi-Qar Province, Iraq

Article History:

Received on: 12.05.2018

Revised on: 21.08.2018

Accepted on: 23.08.2018

Keywords:

Molluscum contagiosum (MC),
Al-Nassiria,

ABSTRACT

Molluscum contagiosum is a viral disease of the skin characterized by discrete, multiple, flesh-coloured or shiny papules. Molluscum contagiosum is common in immunocompromised patients, sexually active adults and children. There are increases in the incidence of molluscum contagiosum among Iraqi patient needs further study. The study aims to provide the characteristics and the clinical features of MC on a series of patients in Al-Nassiria city. Evaluation of 120 patients was conducted in Al-Hussein teaching Hospital in Al-Nassiria, Iraq, Patients with MC were diagnosed clinically by two dermatologists in the dermatology department. Over the study period, data of these patients were collected and analysis was done as follows: patient age and gender, duration of the disease in months, site, and history of atopic dermatitis. 120 patients entered this study. That mean age of the patients at present study was 29.5 16.7 years range (1-70years). The patients between (1-10year) had the 1st peak of incidence of disease, patients 38 of 120 (31.7%), the child specifically between children aged 1-4 years are 31 of 38 patients. MC lesions were presented mainly at the right side of the face in 79 patients (80.6%) compared to the left side of the face in 19 (19.4%) the P value was also < 0. 001. We conclude that patient with This survey has demonstrated that Molluscum contagiosum is a common skin infection. Molluscum contagiosum papules most commonly develop on the face on right side.



* Corresponding Author

Name: Alaa Naif

Email: alaanife_77@yahoo.com

ISSN: 0975-7538

DOI: <https://doi.org/10.26452/ijrps.v9i4.1684>

Production and Hosted by

Pharmascope.org

© 2018 Pharmascope Publications. All rights reserved.

INTRODUCTION

Molluscum contagiosum is a viral disease of the skin characterized by discrete, multiple, flesh-coloured or shiny papules. It is caused by a highly infectious, enveloped deoxyribonucleic acid virus, called molluscum contagiosum virus (MCV) causes a benign self-limiting condition. Molluscum contagiosum is common in immunocompromised patients, sexually active adults and in children

(Ramdass *et al.*, 2015; Chen *et al.*, 2013) the transmission of the virus occur during direct skin-to-skin contact. Adults are infected usually through sexual contact.

Intimate skin-to-skin contact is sufficient for transmission of the virus (Chen *et al.*, 2013). The lesions differ in dimension (from 1 mm to 1 cm in diameter) and are painless, although a subset of patients reports pruritus or pain in the region of infection. On average, 11-20 papules appear on the body during infection and generally remains a self-limiting disease (Likness, 2011). However, in immunosuppressed patients, molluscum contagiosum can be a severe infection with hundreds of lesions developing on the body. Widespread eruption is indicative of an advanced immunodeficiency state (Basta-Juzbašić and Čević, 2014). Treatment of molluscum contagiosum should be undertaken in an individualized manner, a specific treatment does not exist (Wouden *et al.*, 2018), on the other hand,

prevention is challenging due to the high virus infectivity.

Unusually widespread lesions have been reported in immunosuppressed patients with HIV disease, sarcoidosis and in those receiving immunosuppressive therapy, suggesting that cell-mediated immunity has a significant role in control and elimination of the infection (Stock, 2013) People who are at increased risk for getting the disease include people who live in warm, humid climates and where living conditions are crowded (Olsen *et al.*, 2014) Such conditions are present in Al-Nassiria city. However, the incidence of Molluscum contagiosum in Iraq is largely unknown.

AIM OF STUDY

To evaluate the characteristics and the clinical features of MC on a series of patients in Al-Nassiria city.

Patients and Methods

A study of 120 patients was conducted in Al-Hussein teaching Hospital in Al-Nassiria, Iraq over a period of 11 months (from February 2016 to January 2017). Patients with MC were diagnosed clinically by two dermatologists in the dermatology department. Over the study period, data of these patients were collected and analysis was done as follows: patient age and gender, duration of the disease in months, site, number of the lesions, family history and sit of lesions.

RESULTS

1-Patient Characteristics

120 patients entered this study. Table or figure (1) showed that the mean age of the patients at present study was 29.5 ± 16.7 years range (1-70years). The patients between (1-10year) had the 1st peak of incidence patients 38 of 120 (31.7%), the child specifically between children aged 1-4 years are 31 of 38 patients. There were 81 (67.5%) males and 39 (32.5%) females. The duration of MC disease before presentation ranged from (1- 12 months) with 1-3 months in (57.5%) of the patients, 7-12 months in (17.5%) of the patients and from 4-6 months in (25%) of the patients. 28 patients (23.3%) present with a family history of molluscum, History of atopy is presented in 38 patients (31.7%).

2 -site and facts of MC Lesions

The distribution of the patients' MC lesions is presented in the figure. Molluscum contagiosum lesions were limited to 1 region in 100 patients (83.3%) and lesions were present on multiple sites in 20 patients (16.7%). The following distribution: face 98(81.7%), genitalia 7 (5.8 %) and Others (scalp, neck, trunk) 15 patients (12.5 %), a highly

significant statistical difference (P values less than 0.001) when we compare the distribution of the MC lesions at the face with the distributions at the genitalia, and (scalp, neck, trunk) respectively.

There was also a highly significant statistical difference between the distributions of the MC lesions at the two sides of the face (the MC lesions were presented mainly at the right side of the face in 79 patients (80.6%) compared to the left side of the face in 19 (19.4%) the P value was also < 0.001.

There was also a highly significant statistical difference between the Size of lesions of the M.C. (the M.C. lesions were presented mainly at a size (- 4 2mm) in 87 patients (72.5%) compared to the other side of the(less than 2 mm) in 2 patients (1.7%) in), (4- 6 mm) in 18 patients (15%), (6-8mm) in 10 patients (8.3%) and(more 8 mm) in 3 patients (2.5%) the P value was also < 0.001).

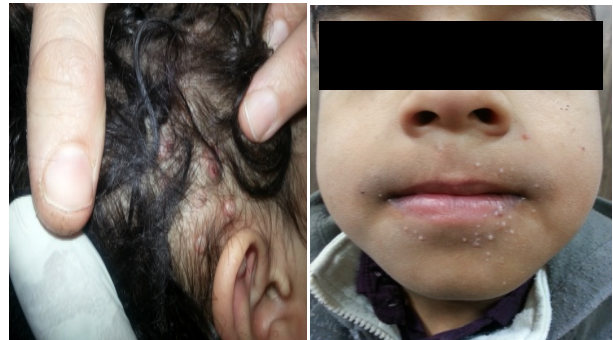

Figure 1: A child present with multiple MC I Lesion

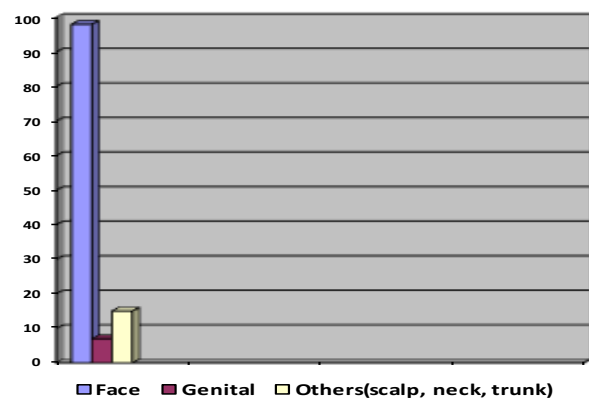


Figure 2: Site of Molluscum contagiosum (MC) lesions

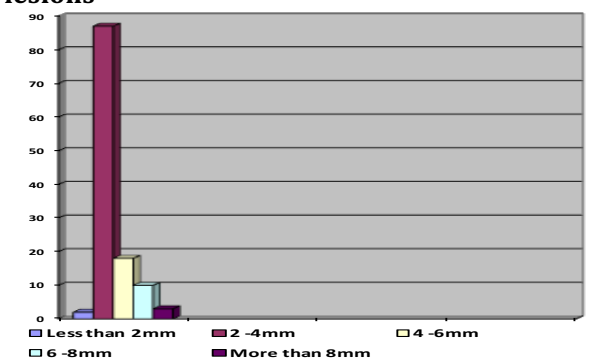


Figure 3: Size of Molluscum contagiosum (MC) lesions

Table 1: Location of MC according to the body site

Site	%
Face	98 (81.7%)
Mainly right sided	79(80.7%)
Mainly left sided	19(19.3%)
Genitalia	7 (5.8%)
Multiple sites (Trunk +/- Extremities +/- Face)	15 (12.5%)

DISCUSSION

Molluscum contagiosum is a common cutaneous viral infection, but its incidence in most areas of the world is not reliably known (Basta-Juzbašić and Čeović, 2014). In Iraq, in the last few years, there was an increase in the incidence of MC compared with other dermatological diseases which made a load for the health centre and patients at the same time, there are limited numbers of publications about the occurrence of the MC among the Iraqi population with a constricted range of cases, This increase in MC infection may be due to a social factor were a lot of families have a relatively large number of children, about four on average, or more big families, a large number of people were grouped during social and religious events using the same contaminated surfaces or objects for example towels and beds, this helps in spreading the virus by direct skin to skin contact. The patients between (1-10year) had the 1st peak of incidence patients, this result agrees with Published data showing a higher incidence of MC in American child, specifically amongst children aged 1–4 years (Olsen *et al.*, 2014). The disease is rare under the age of 1 year, perhaps because of transmission of maternal immunity and because of the long incubation period (Olsen *et al.*, 2014), a number of authors have hypothesized that children in this age range have behaviours and actions that make easy direct contact with infected people (Wouden *et al.*, 2018), the face was significantly involved (P values less than 0.001) in comparison to other sites involved highly significant statistical difference between the distributions of the MC at the two sides of the face (right side more involve). This result agrees with Usama study that's been done in Al-Diwaniya, Iraq (Abdul-Jaleel, 2014). The lesions were usually on the right side of the face and the reason was the way of greeting where people shake right hands of each other and kiss the right cheeks of each other.

In our study lesions were presented mainly at a size (2-4mm) in 87 patients, the lesions typically present as asymptomatic, dome-shaped, flesh-coloured papules. Similar to other studies were the lesion size usually below 5 mm, the data reported by Hong Sun Jang *et al.* were the physical examination,

indicate 2 to 3 mm sized skin-coloured papules the major size (Jang *et al.*, 2013).

The majority of patients have a duration of disease below three months duration (57.5% of patients that enrolled in the study), and this agrees with the hypothesis of MC infection may persist for a month to a year (Vardhan *et al.*, 2010).

History of atopy (atopic dermatitis, asthma and allergic rhinitis) may increase the susceptibility to infection due to immune dysfunction and barrier dysfunction in the atopic skin (Netchiporouk and Cohen, 2012). The history of atopy has a high association with molluscum. Over a third of the Molluscum contagiosum patients in the present study had a finding of eczema or dermatitis, a remarkably high frequency of diagnoses compared to other data. In an available data by Berger, *et al.*, a high fraction of Molluscum contagiosum patients (37.2%) had a history of atopic dermatitis (Berger *et al.*, 2012). It is unidentified if the co-exciting of the high prevalence of eczema and Molluscum contagiosum are linked. The present study affirms the association between atopic dermatitis and Molluscum contagiosum; however, the mechanisms of such association are unknown and need more interest and study.

CONCLUSION

This survey has demonstrated that Molluscum contagiosum is a common skin infection seen by many types of health care providers and therefore guidance on treatment considerations and infection control is valuable. Molluscum contagiosum papules most commonly develop on the face on right side. Further study are recommended.

Acknowledgement

We would like to thank Al-Hussain teaching hospital dermatology department. This work was funded by Thi-Qar University.

REFERENCES

- Basta-Juzbašić, A; Čeović, R.2014. "Chancroid, lymphogranuloma venereum, granuloma inguinale, genital herpes simplex infection, and molluscum contagiosum". Clinics in Dermatology (Review). 32 (2): 290–8.
- Berger EM, Orlow SJ, Patel RR, Schaffer JV.2012. Experience with molluscum contagiosum and associated inflammatory reactions in a pediatric dermatology practice: the bump that rashes. Arch Dermatol. 148: 1257–1264.
- Chen, X; Anstey, AV; Bugert, JJ.2013. "Molluscum contagiosum virus infection". Lancet Infectious Diseases, 13 (10): 877–88

- Hong Sun Jang, Mi Ri Kim, Sang Ho Oh.2013. " Un-usual Manifestation of Molluscum Contagiosum: Eruptive Papules on the Face and Neck of an Immunocompetent Patient".
- Likness, LP.2011. "Common dermatologic infections in athletes and return-to-play guidelines". The Journal of the American Osteopathic Association, 111 (6): 373–379.
- Netchiporouk E, Cohen BA.2012. Recognizing and managing eczematous ID reactions to molluscum contagiosum virus in children. Paediatrics, 129 1072–10751
- Olsen JR, Gallacher J, Piquet V, Francis NA.2014. Epidemiology of molluscum contagiosum in children: a systematic review. Fam Pract.31(2):130-136.
- Ramdass, P; Mullick, S; Farber, HF.2015. "Viral Skin Diseases". Primary Care (Review). 42 (4): 517–67
- Stock I:2013. Molluscum contagiosum -- a common but poorly understood "childhood disease" and sexually transmitted illness. Med Monatsschr Pharm. 36(8):282-290
- Usama Abdul-Jaleel Althuwayni.2014. Experience with Molluscum Contagiosum: A Descriptive (Case- Series) Study of 467 Patients in Al-Diwaniya and Evaluation of Their Modes of Treatment Medical Journal of Babylon, Vol. 11- No. 4.
- van der Wouden, Johannes C; van der Sande, Renske; Kruithof, Emma J; Sollie, Annet; van Suijlekom-Smit, Lisette WA; Koning, Sander.2017."Interventions for cutaneous molluscum contagiosum". Cochrane Database of Systematic Reviews.
- Vardhan P, Goel S, Goyal G, Kumar N.2010. Solitary giant molluscum contagiosum is presenting as a lid tumour in an immunocompetent child. Indian J Ophthalmol.;58(3):236-238.